

# **Navigating the Hybrid Algorithm**

***June 23-24, 2023  
Cors at the Shore***

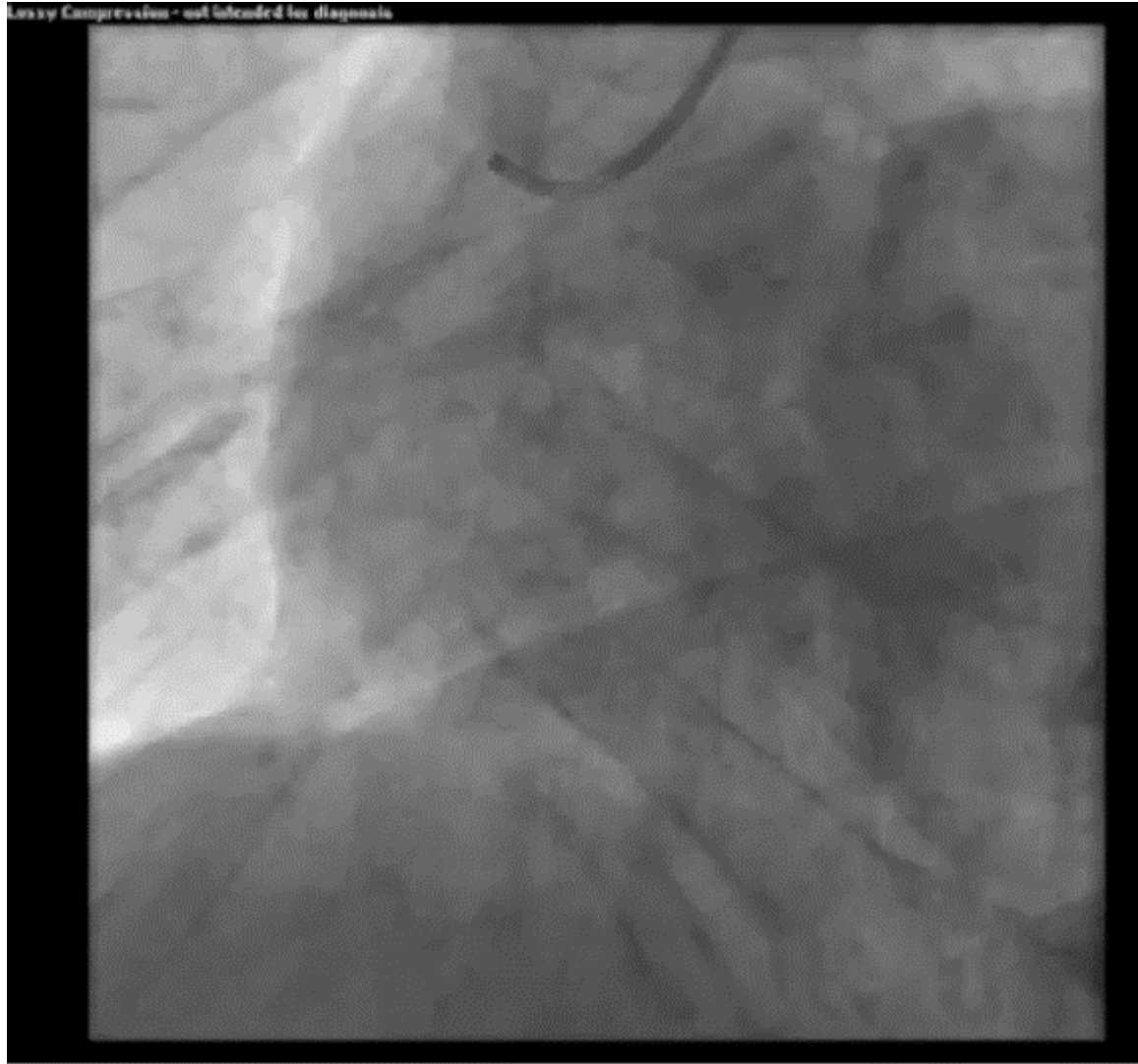***Manish Parikh, MD  
Chief, Division of Cardiology  
New York Presbyterian-Brooklyn Methodist Hospital  
Weill Cornell Medicine***

# Disclosures

- As a faculty member for this program, I disclose the following relationships with industry:
- Speakers Bureau for Abbott Vascular, MDT vascular and Boston Scientific

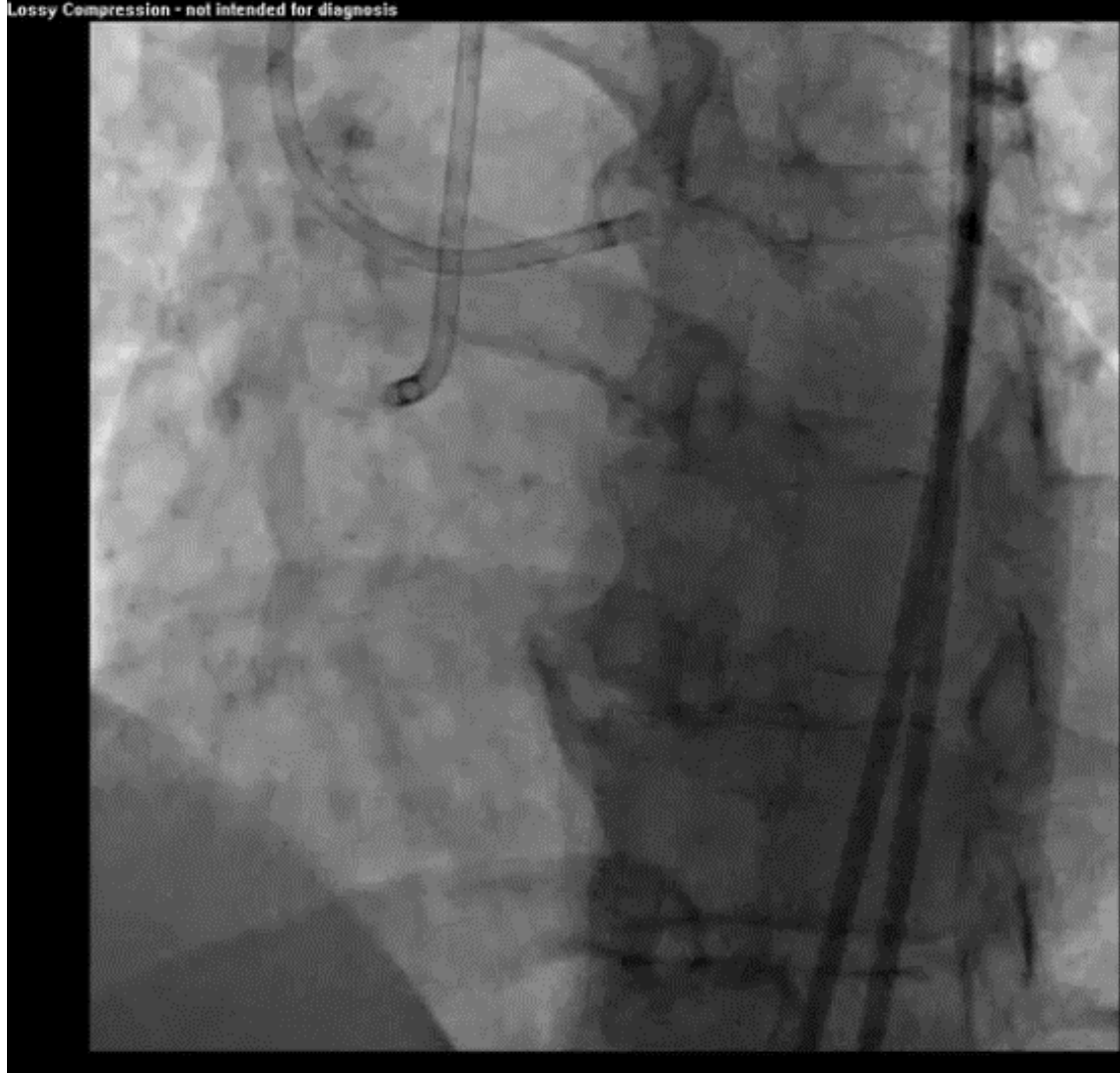
# The CTO Conundrum...

- 55 y.o male with HTN, HLD
- 4 months of exertional angina
- Nuclear stress test positive for inferior wall ischemia with normal EF



# A Different Patient... His identical twin brother

- 55 y.o male with HTN, HLD
- 4 months of exertional angina
- Nuclear stress test positive for inferior wall ischemia with normal EF



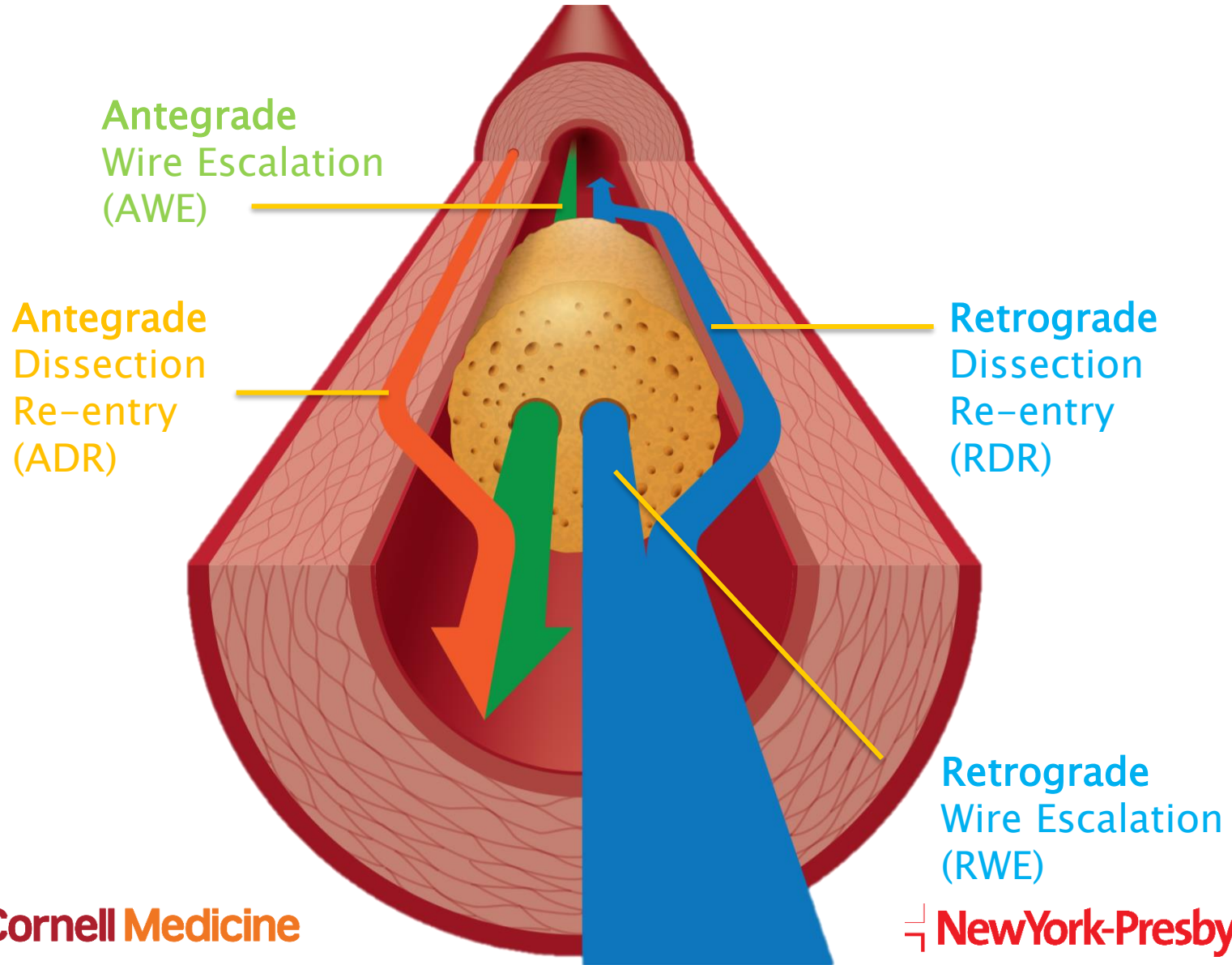
*Why Do We Treat This So Differently?*

# Summary:

## Rationales for CTO Recanalization

- Relief of angina/ischemia (typically exertional symptoms)
- Improvement of ventricular function
- Reduced incidence of late CABG
- Possible Improvement in event-free survival

# 4 options to crossing CTOs



Antegrade  
Wire Escalation  
(AWE)

Antegrade  
Dissection  
Re-entry  
(ADR)

Retrograde  
Dissection  
Re-entry  
(RDR)

Retrograde  
Wire Escalation  
(RWE)

# Guiding Principles for CTO PCI - ABC

## *Success and Time Efficiency*

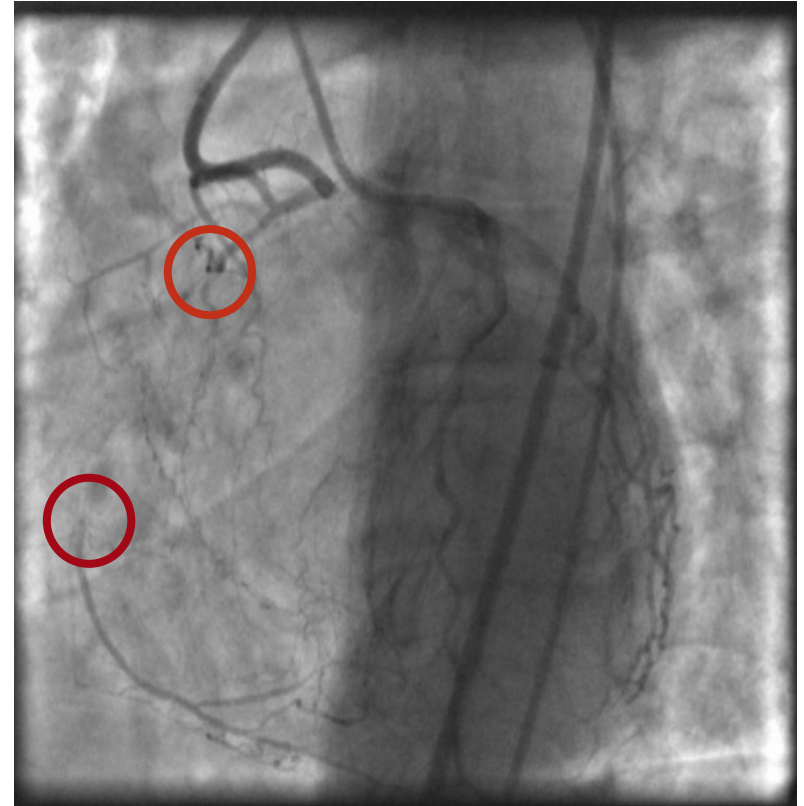
- ANATOMY dictates strategy
  - ***Antegrade***
  - ***Retrograde***
  - ***Reentry***
  - ***Complimentary strategies***
- 'BASE' of Operations
  - *Distal cap for antegrade*
  - *Proximal cap for retrograde*
  - *as quickly as possible*
  - **Have sequential, adaptable strategic contingency plans prepared in advance**
- CHANGE from failing strategy *early*



# The Base of Operations

*the model for effectiveness and efficiency*

- **Antegrade Goal**
  - Move gear safely and quickly to **distal cap** to focus on true lumen entry or...
  - Move gear beyond distal cap to focus on reentry
- **Retrograde Goal**
  - Move gear safely and quickly to **proximal cap** for true lumen entry or reverse CART (dissection connection)
- **Mobile, not fixed, base**
  - Move up and down vessel as circumstances dictate



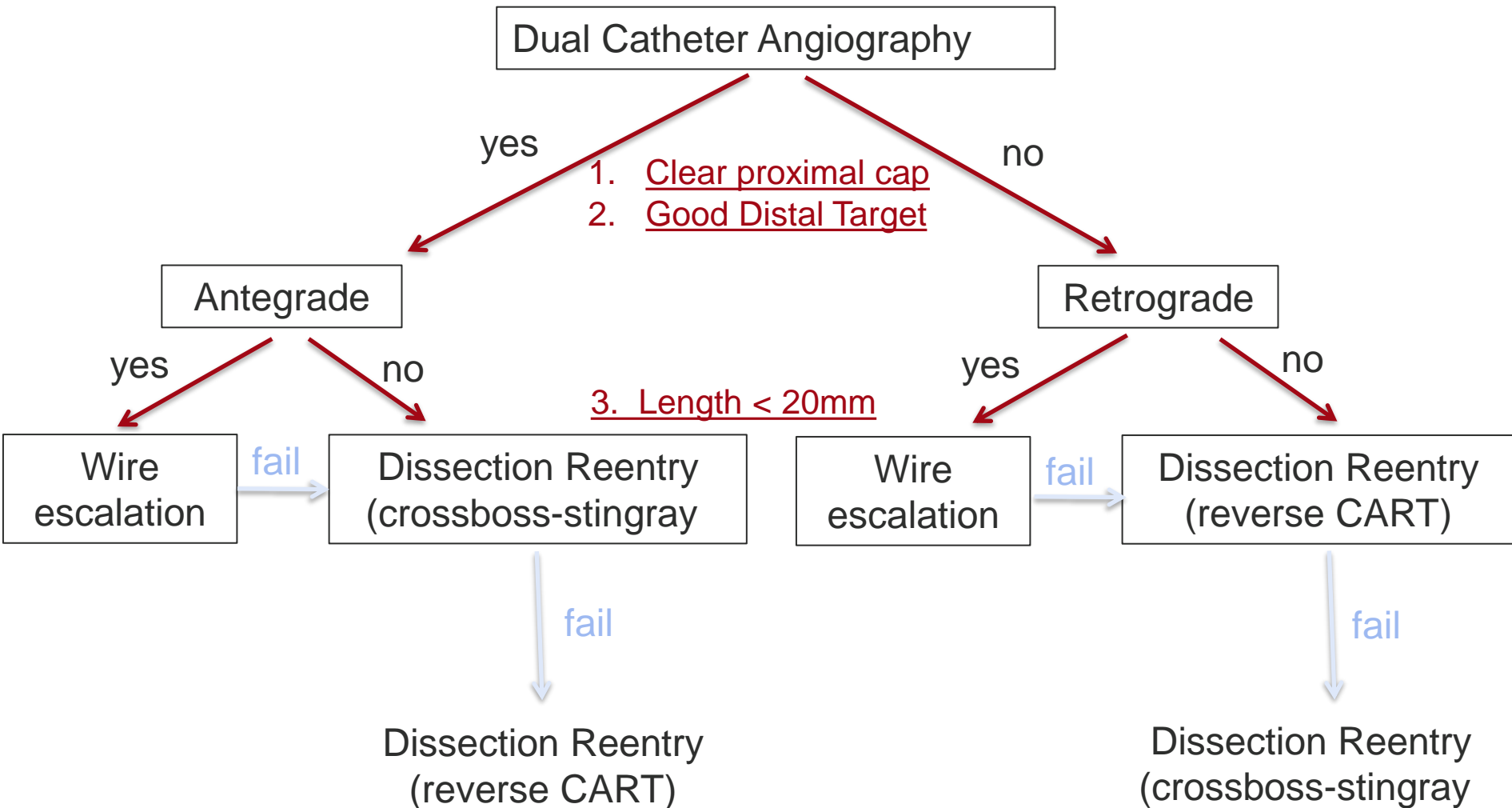
# *Anatomy Dictates Strategy*

## The Four Questions

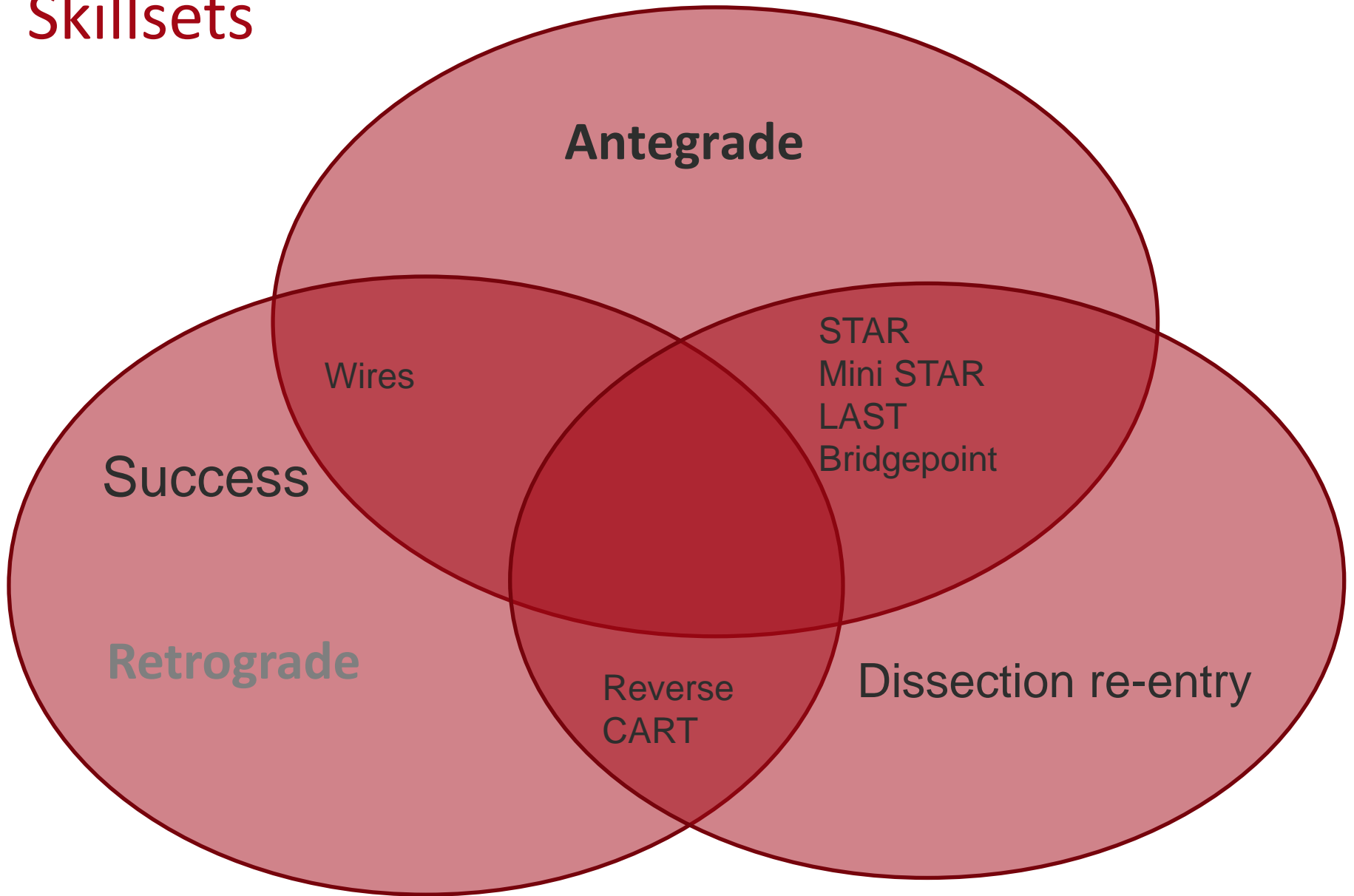
1. Proximal cap
  - **clear by angio +/- IVUS or ambiguous?**
2. Lesion length  $\geq$  20mm
3. Quality of the distal target
  - **Landing zone**
  - **Bifurcation**
4. Suitability of “interventional” collaterals



# The Hybrid Algorithm for CTO PCI




# Skillsets



# Knuckle Wire

- Creating a blunt dissection tool by forward advancing a polymer-jacketed guidewire (Fielder XT or Pilot 200) until it prolapses on itself to form a tight loop which can be advanced past the occlusion in the suboptimal space

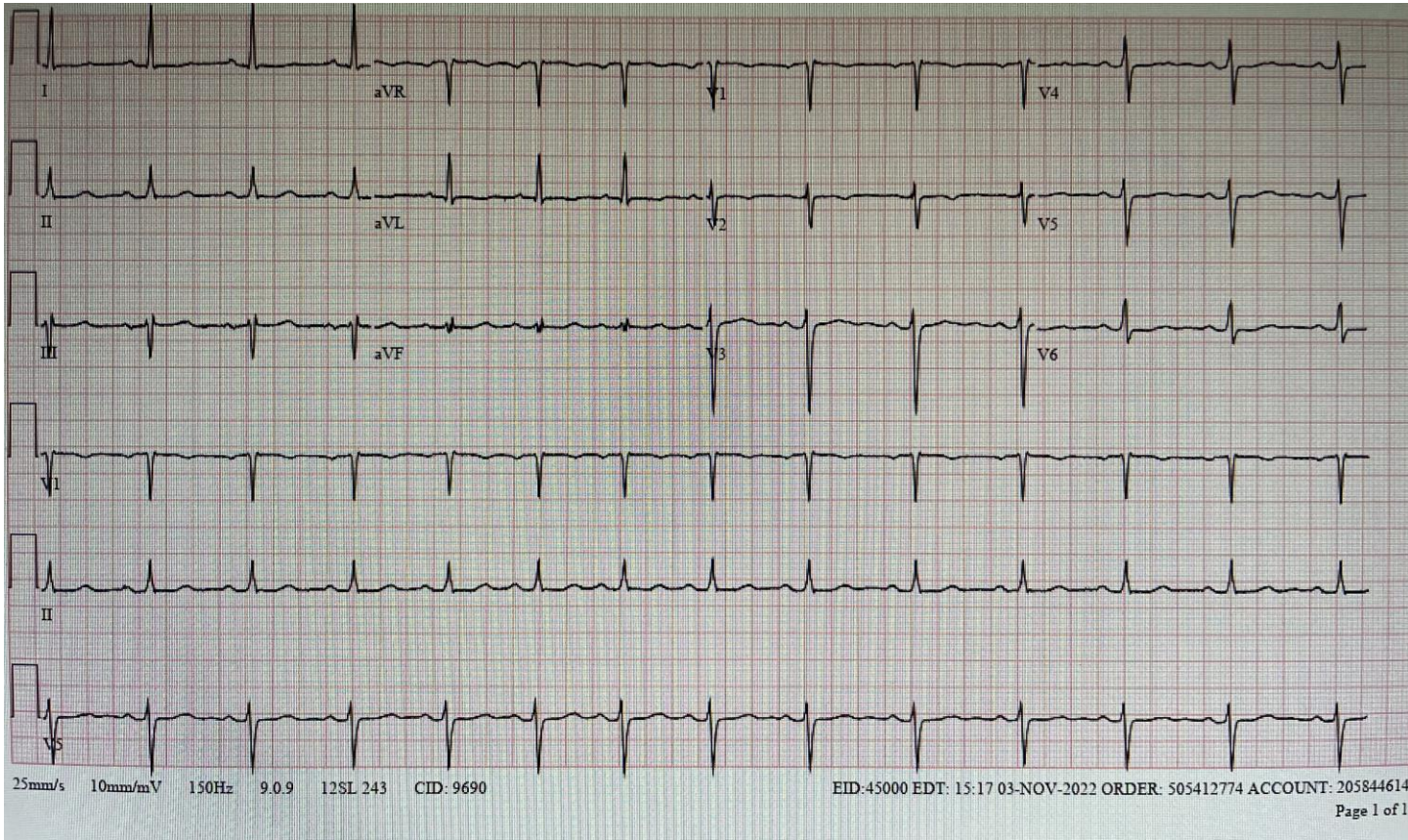


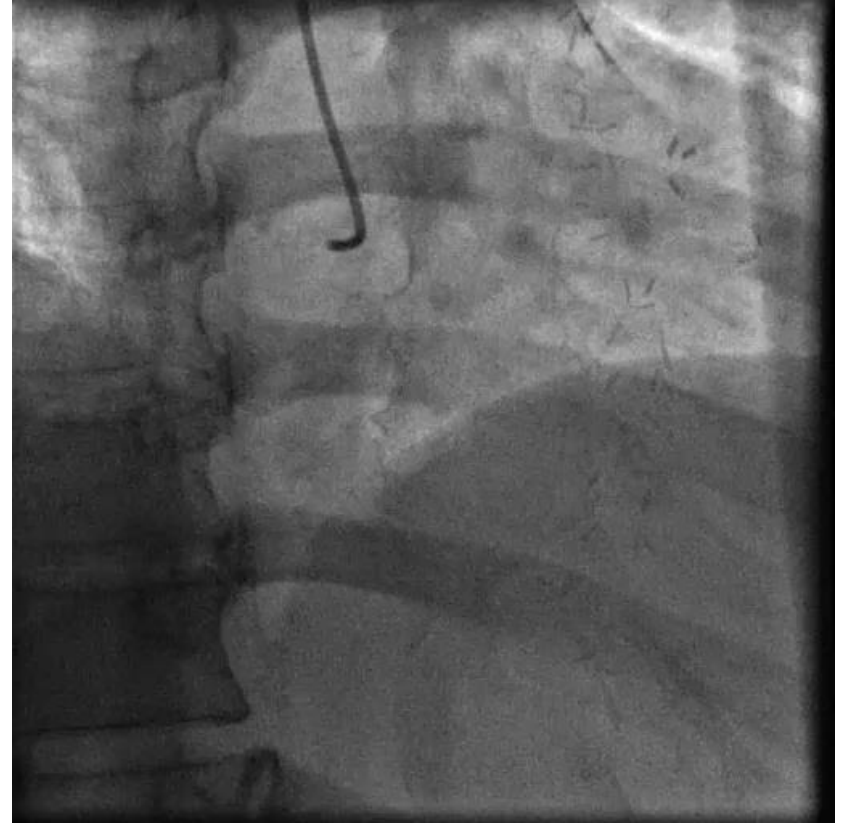
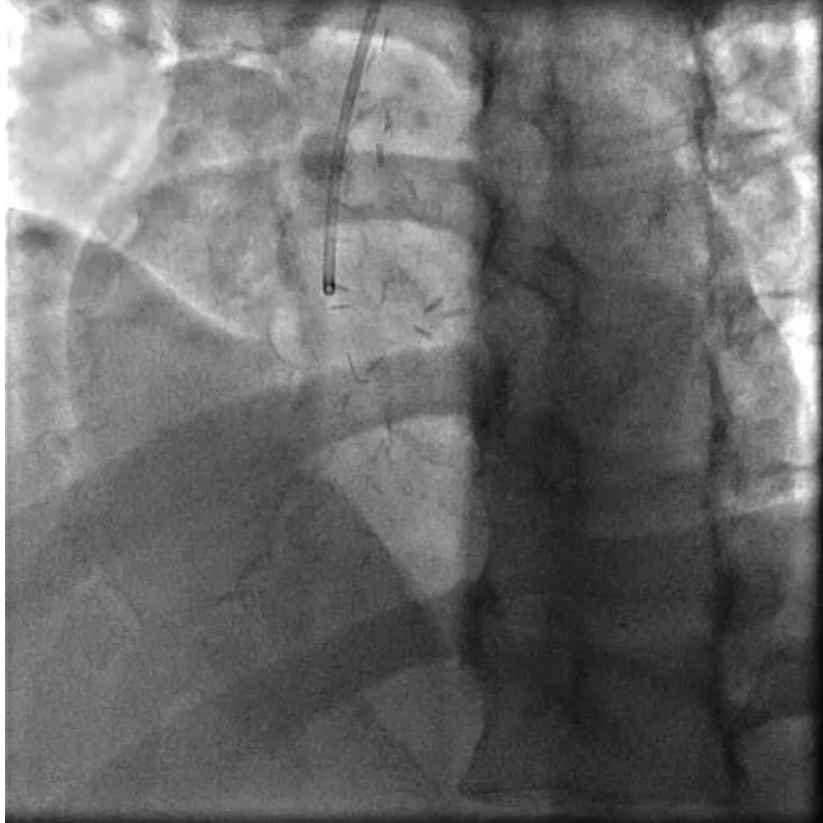
# Antegrade Wire Escalation Case

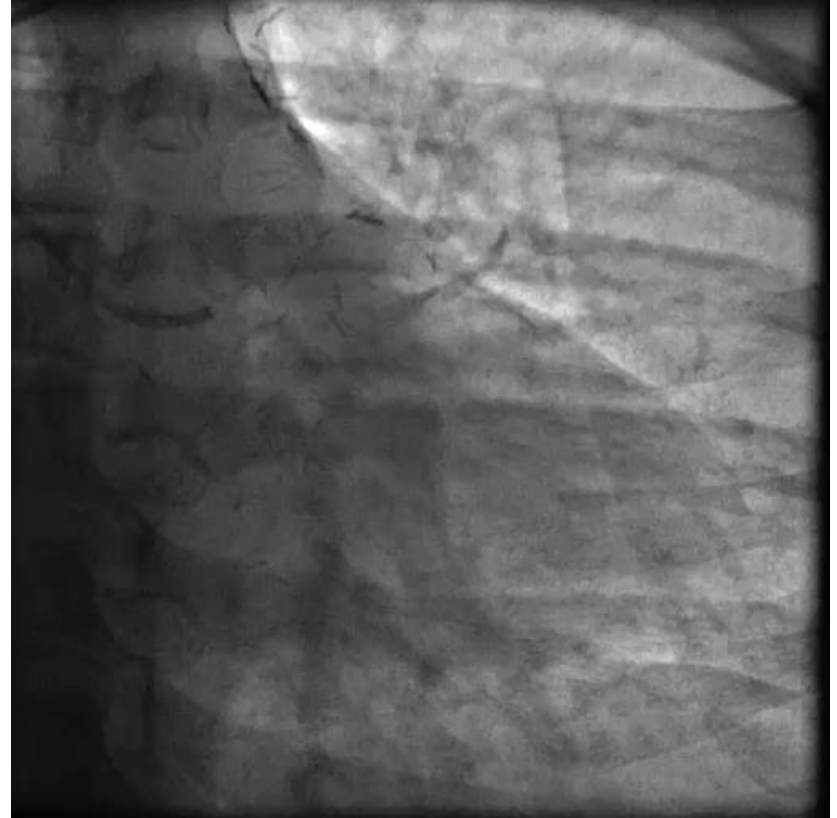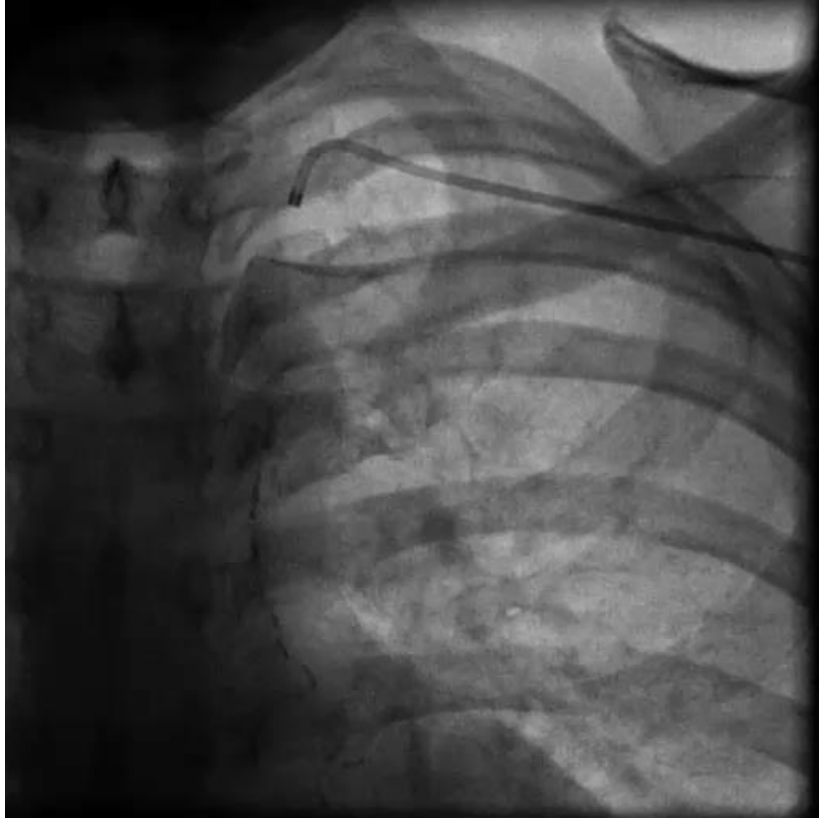## CASE

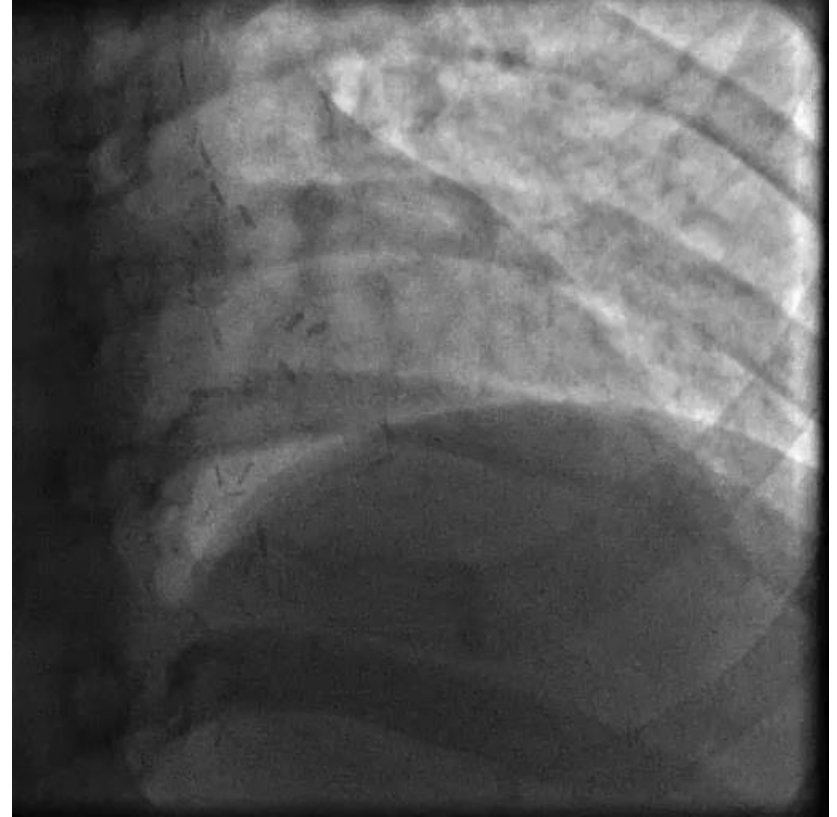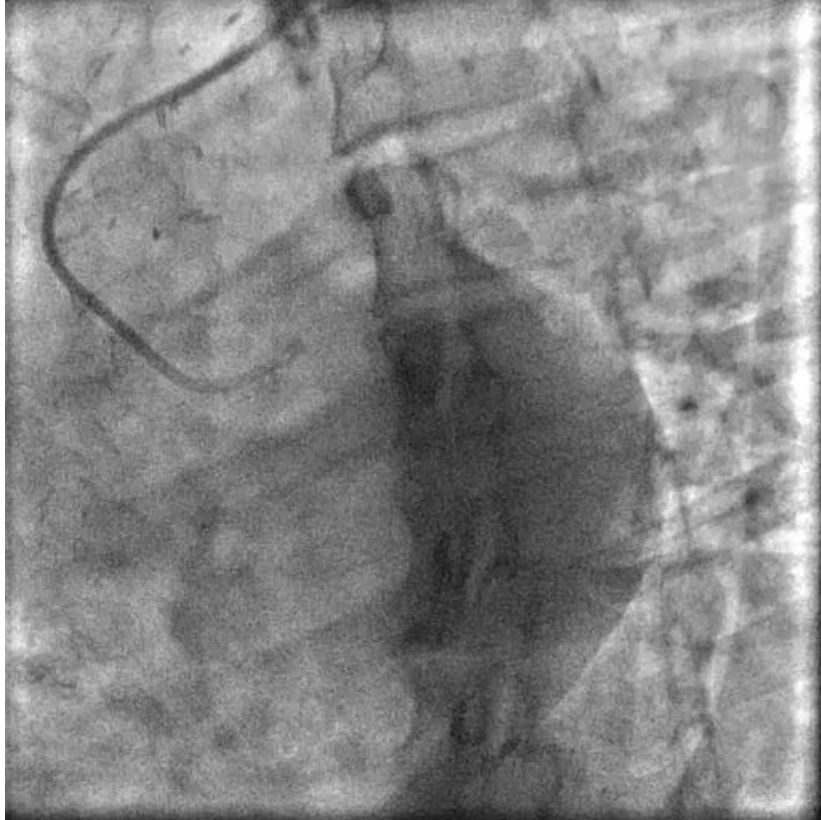- **Chief Complaint:** 38 yo female with dyspnea on exertion and decreased exercise tolerance
- **Past Medical Hx:** HTN, DM, HLD, Single vessel LAD CTO s/p LIMA to LAD in 02/2020
- **Labs:** Hgb/Hct 11.2/33, BUN/Cr 8/0.64

- **Echo:** Normal LVEF, normal wall motion, normal chamber size.
- **Stress Echo: Severe Hypokinesis of the anterior wall with 4 minutes of exercise.**



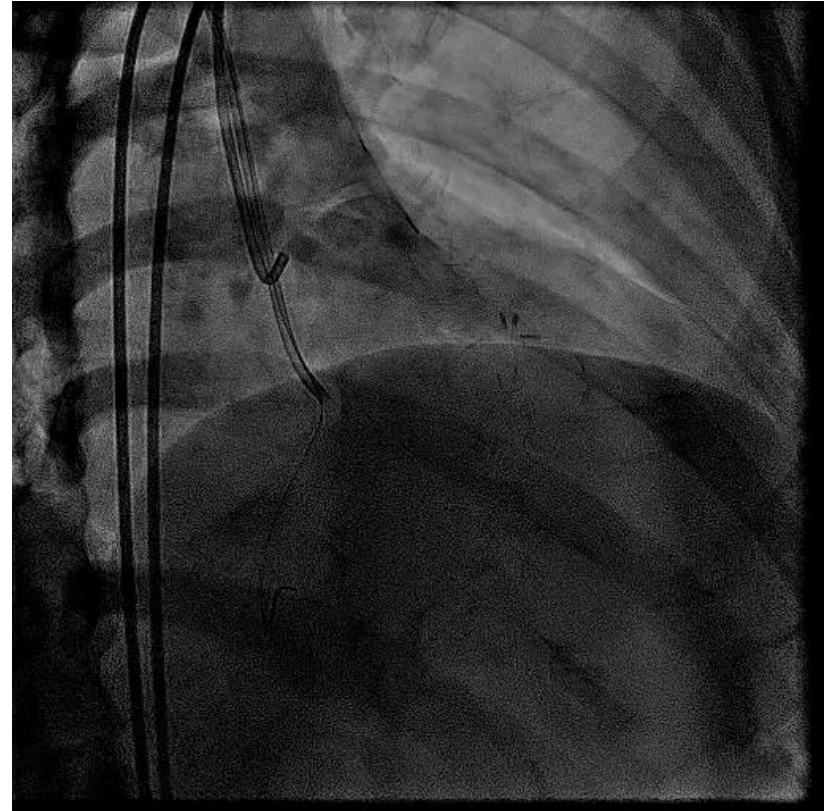
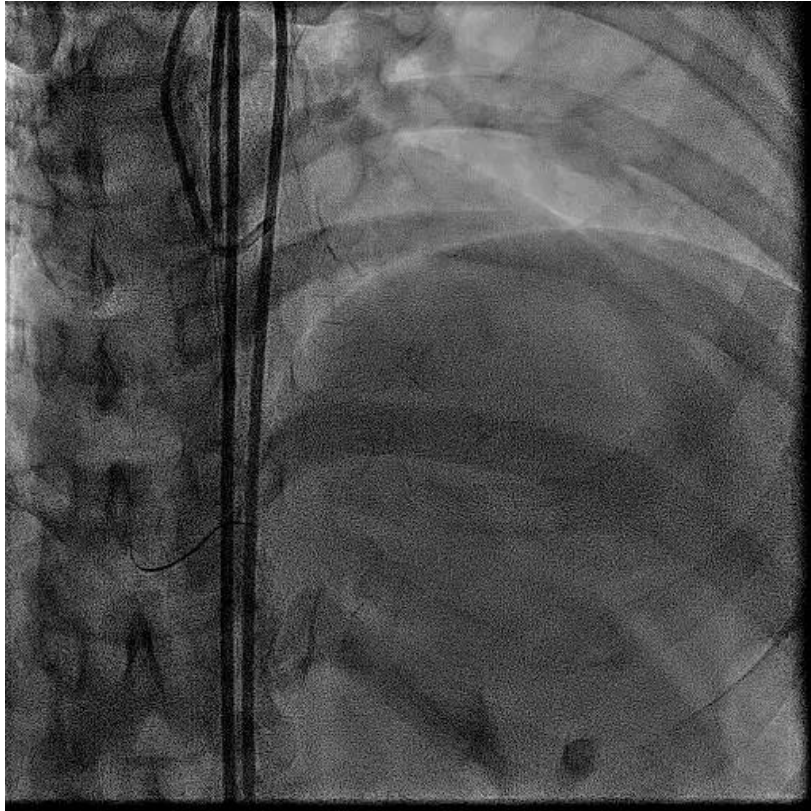




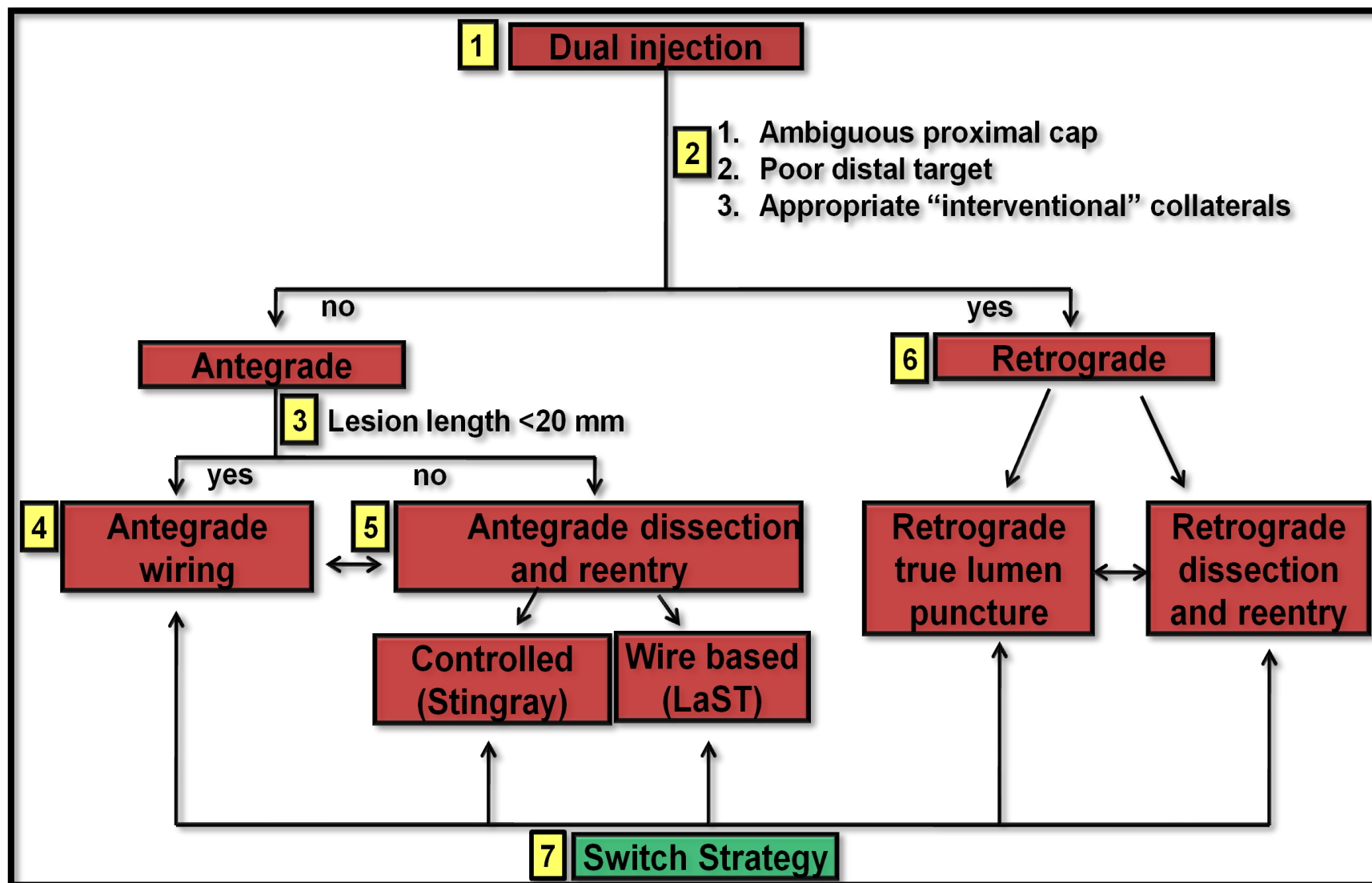


- Patient was treated with medical optimization and risk factor modification with maximal anti-anginal therapy on a beta blocker, calcium channel blocker and nitrates.
- She continues to have worsening shortness of breath upon exertion and angina.
- Patient seeks second opinion
- Patient was offered Re-Do CABG and declined and self referred to our outpatient office at CCH.

# LAD CTO PCI 05/2023

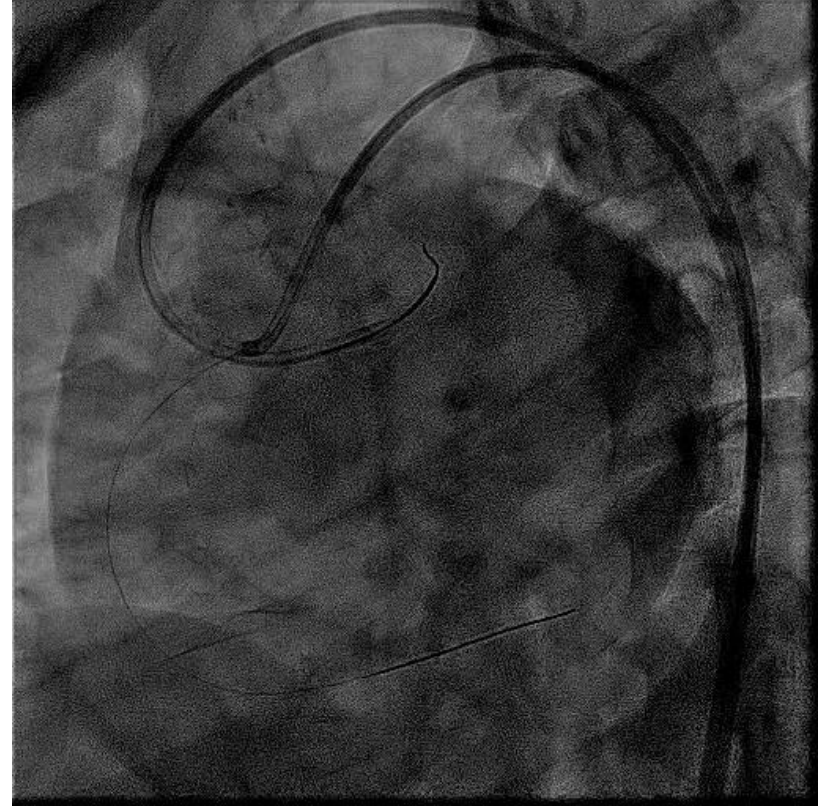
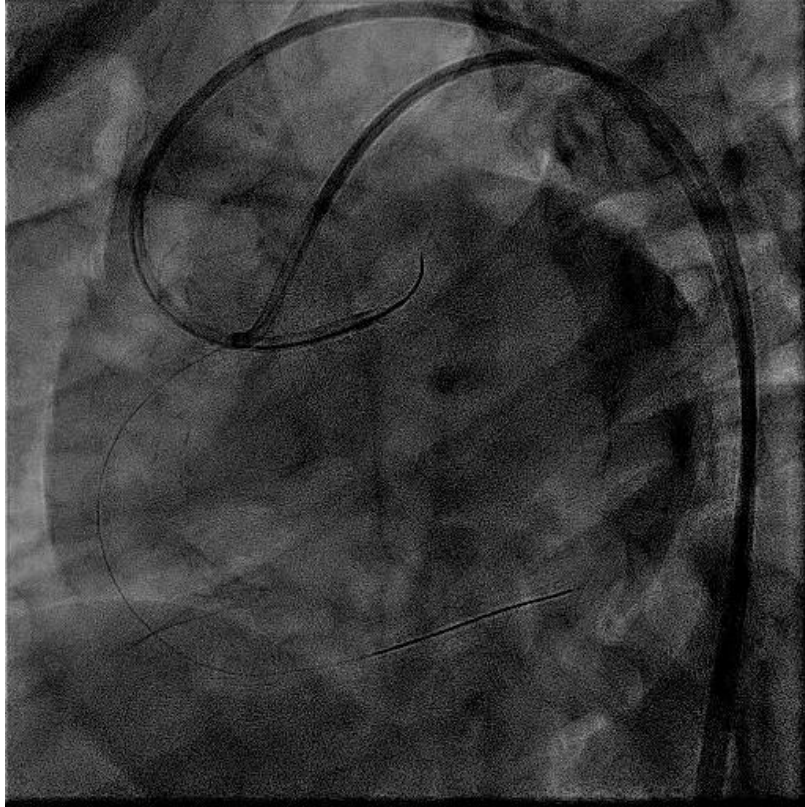


# Hybrid Strategy Treatment Algorithm

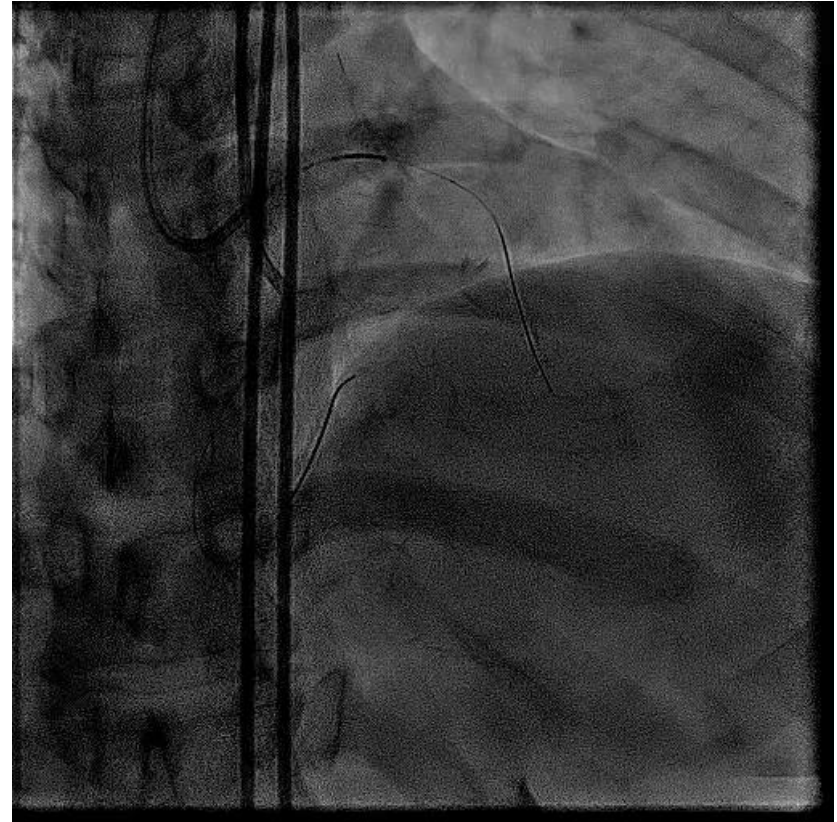
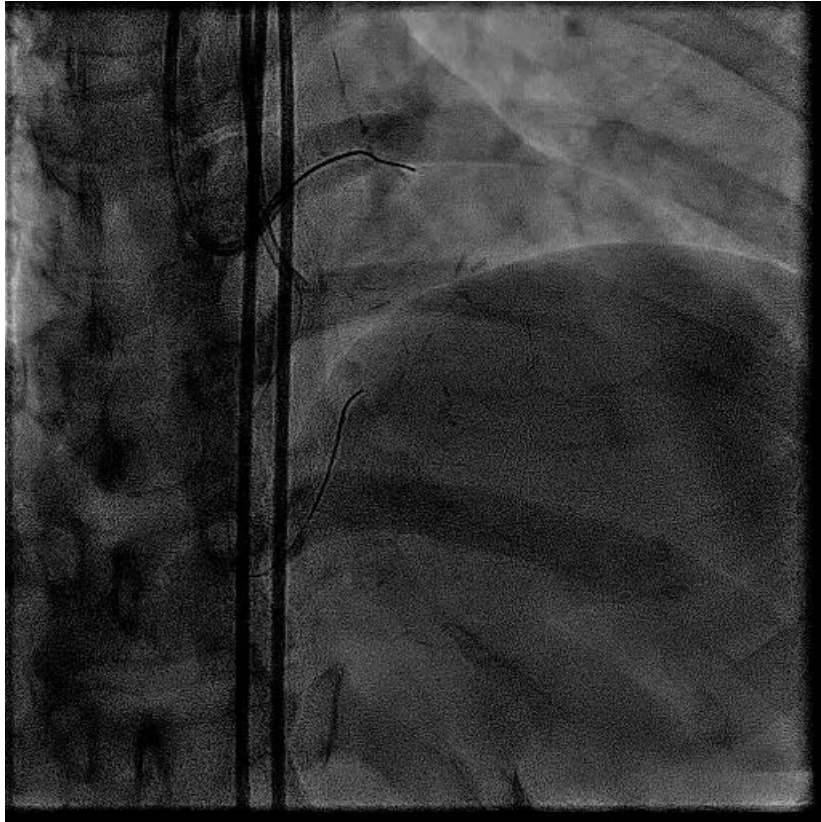


Brilakis et al. JACC: CARDIOVASCULAR INTERVENTIONS, VOL. 5, NO. 4, 2012

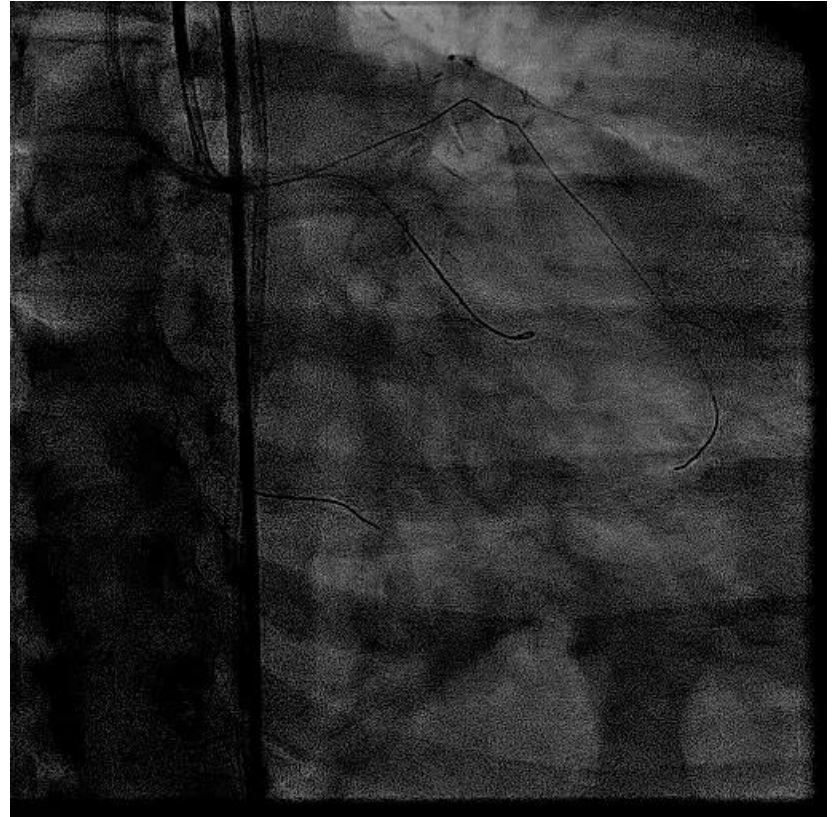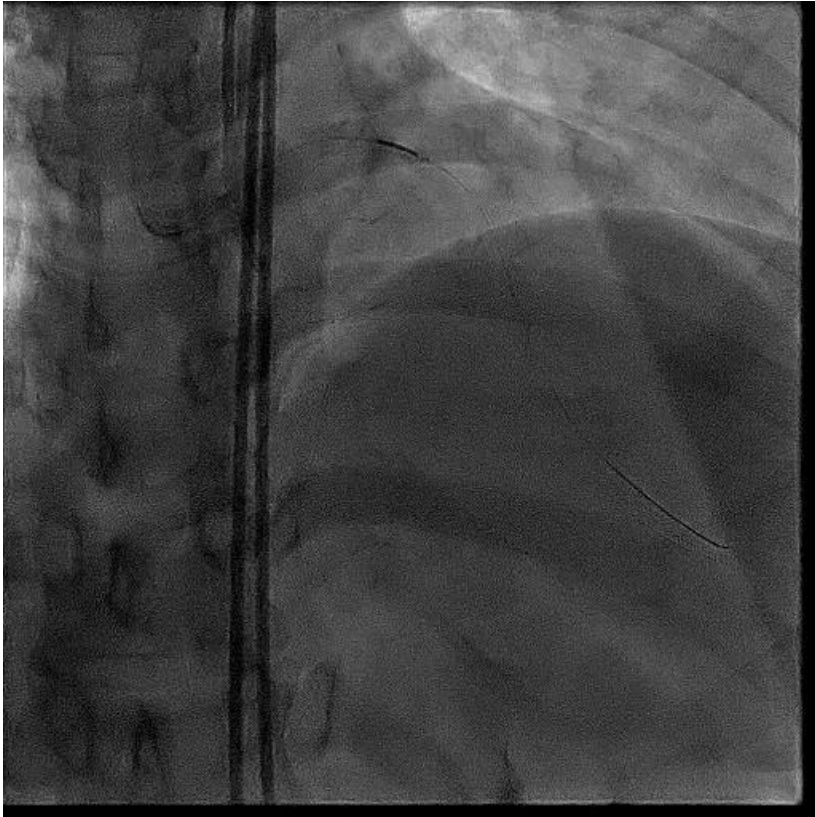
APRIL 2012:389-92



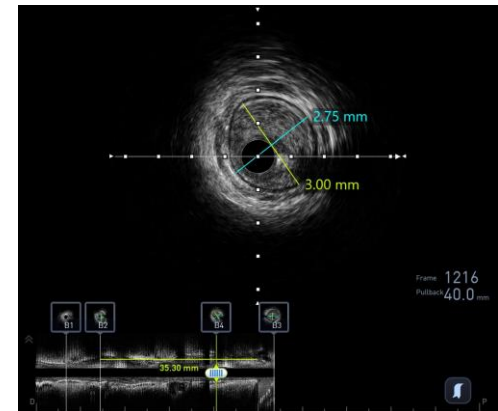
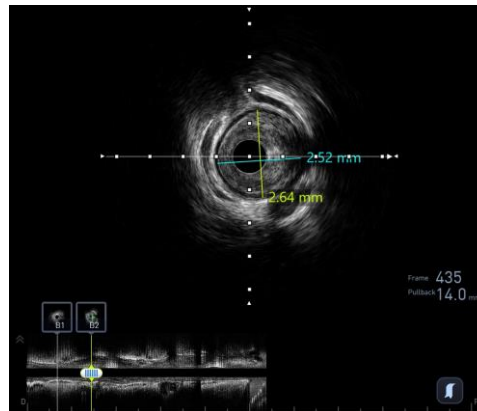
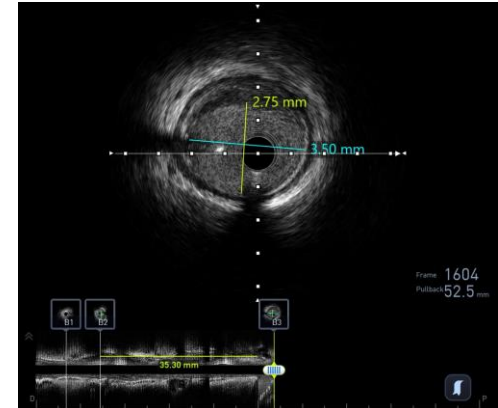
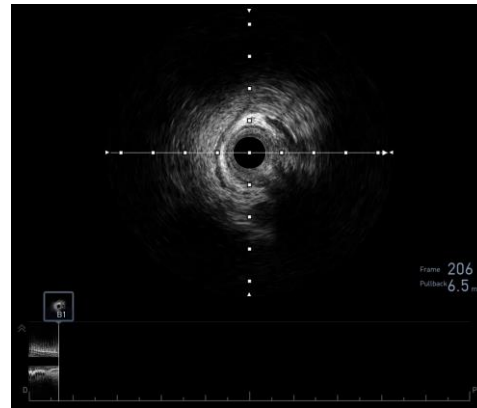
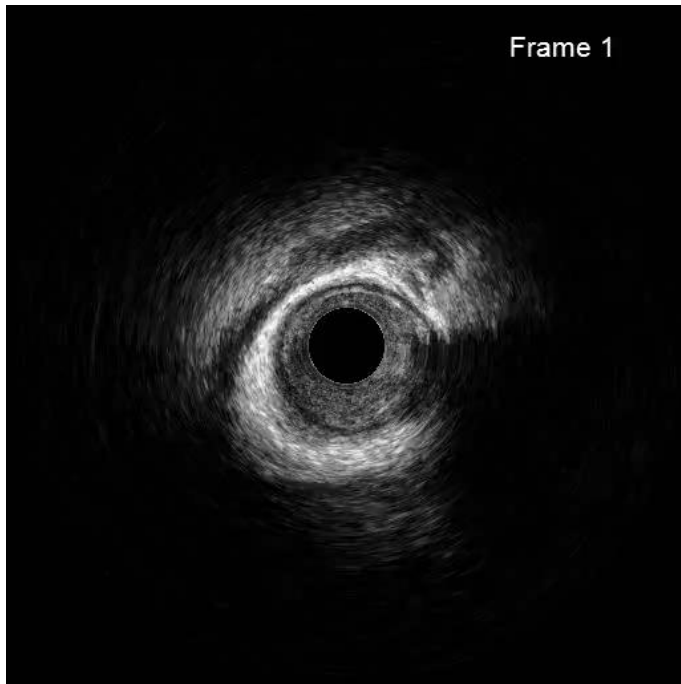
## LAD CTO PCI

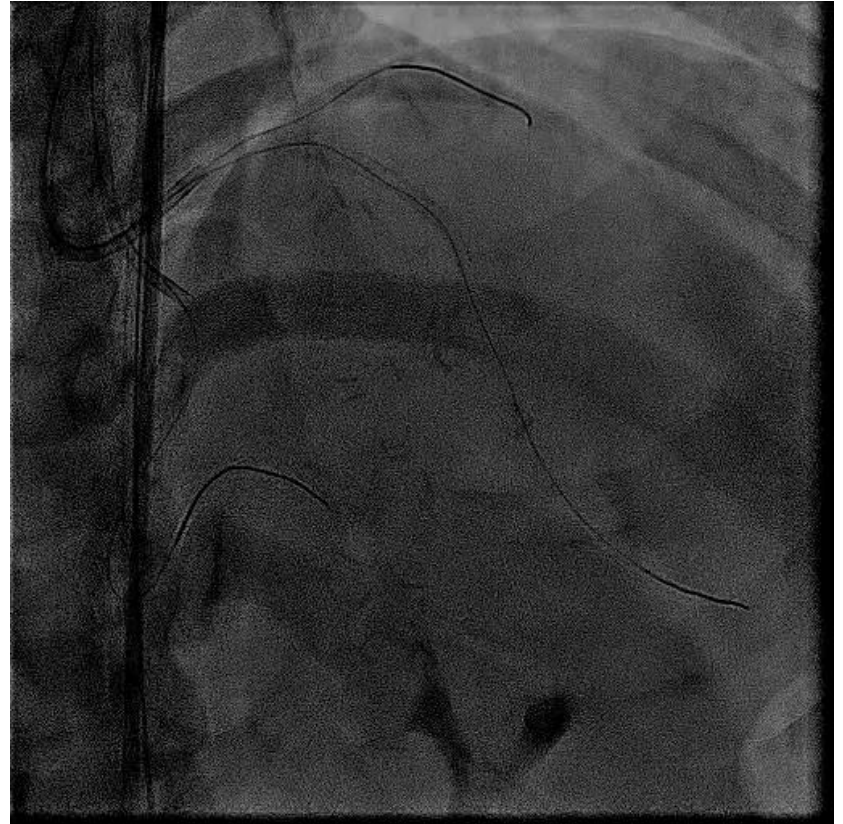
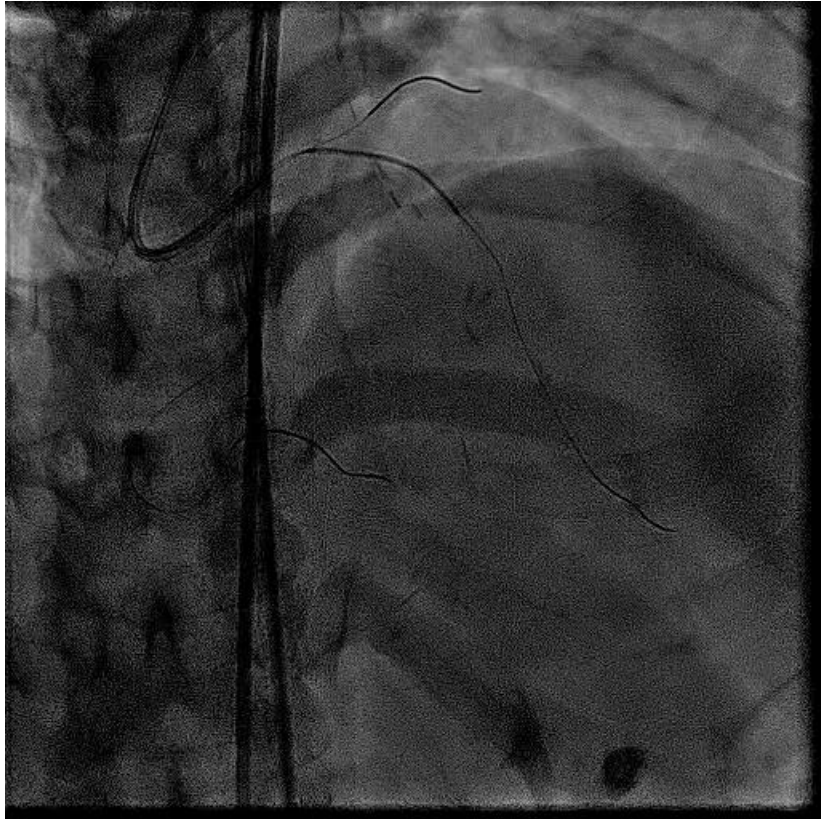


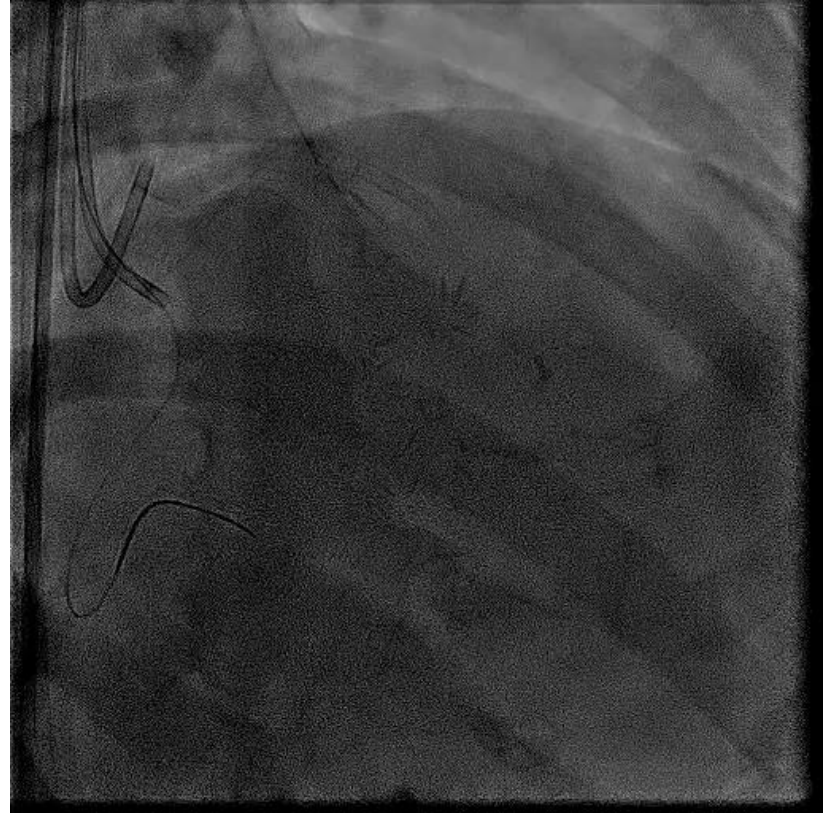
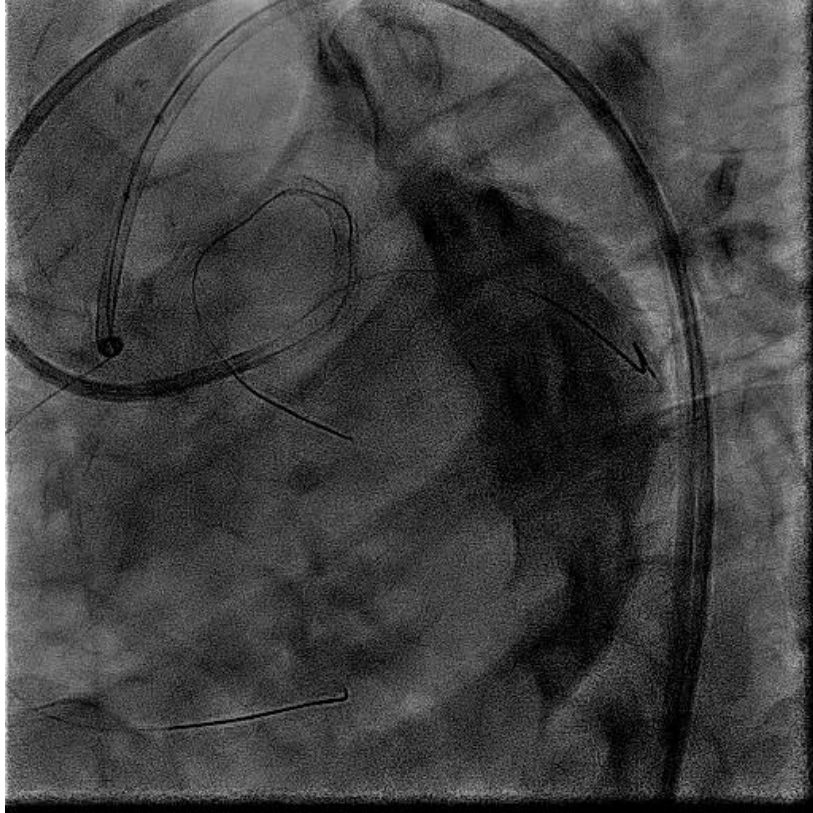## LAD CTO PCI



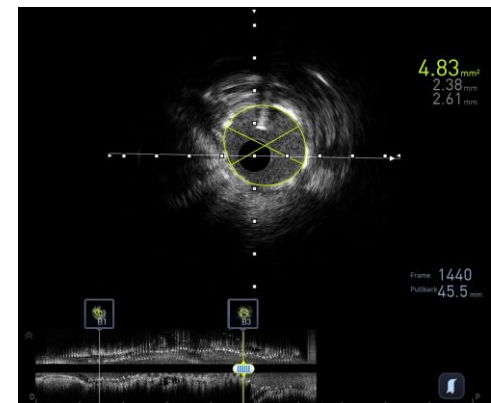
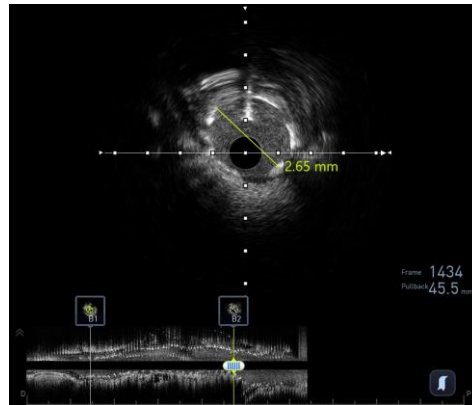
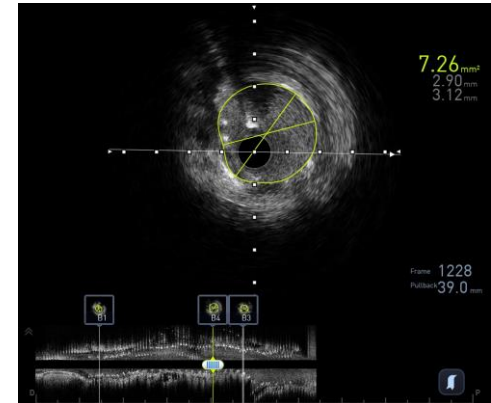
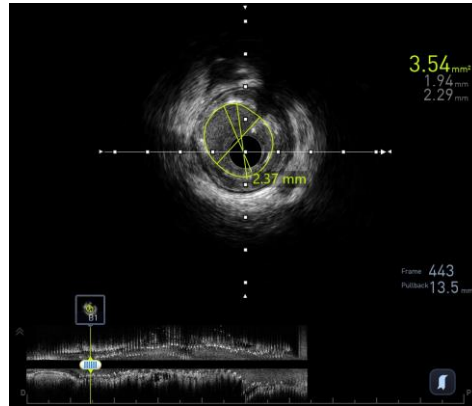
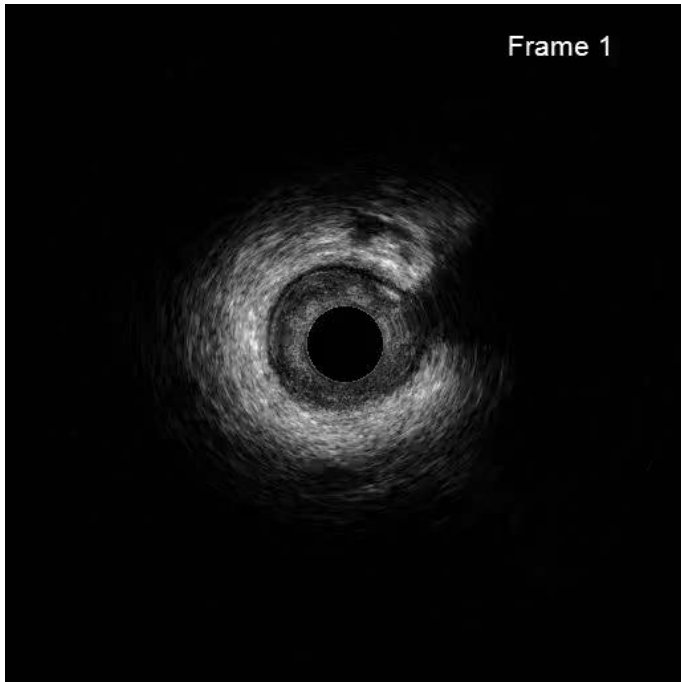
# Intravascular Imaging



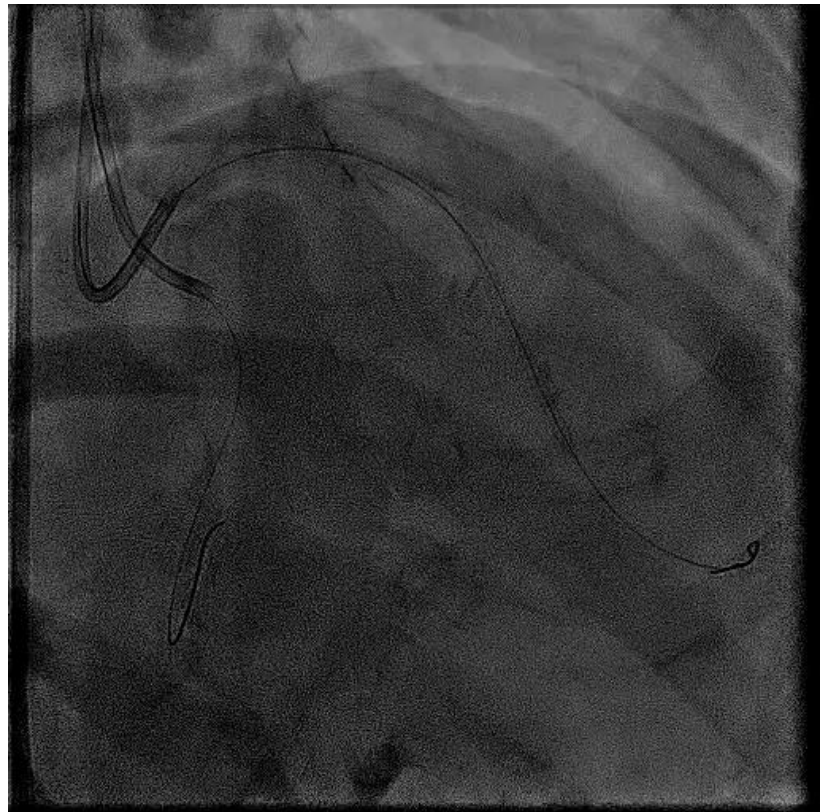
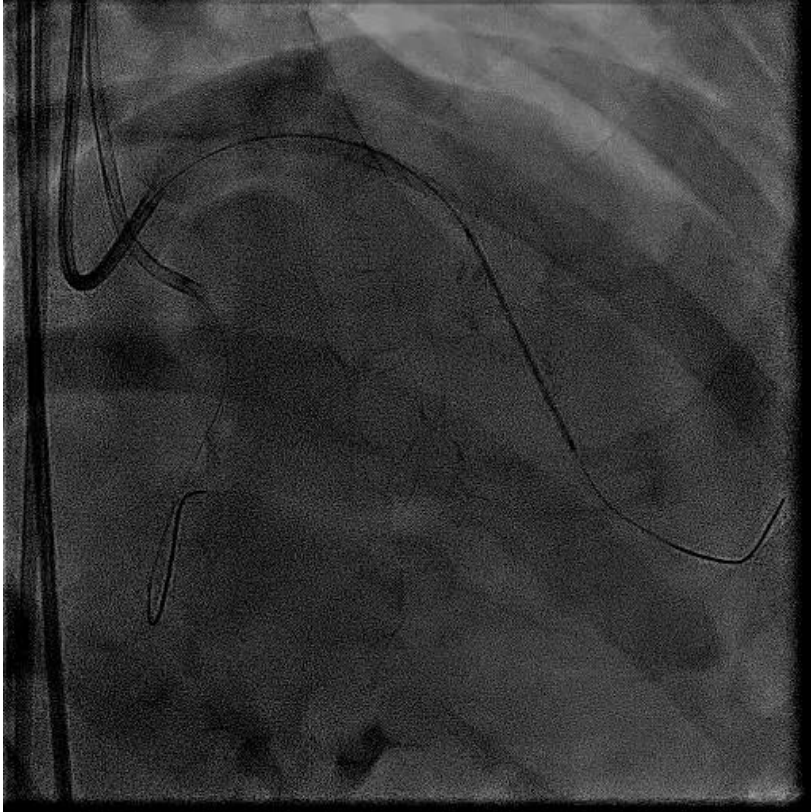




# Intravascular Ultrasound (Are we finished?)

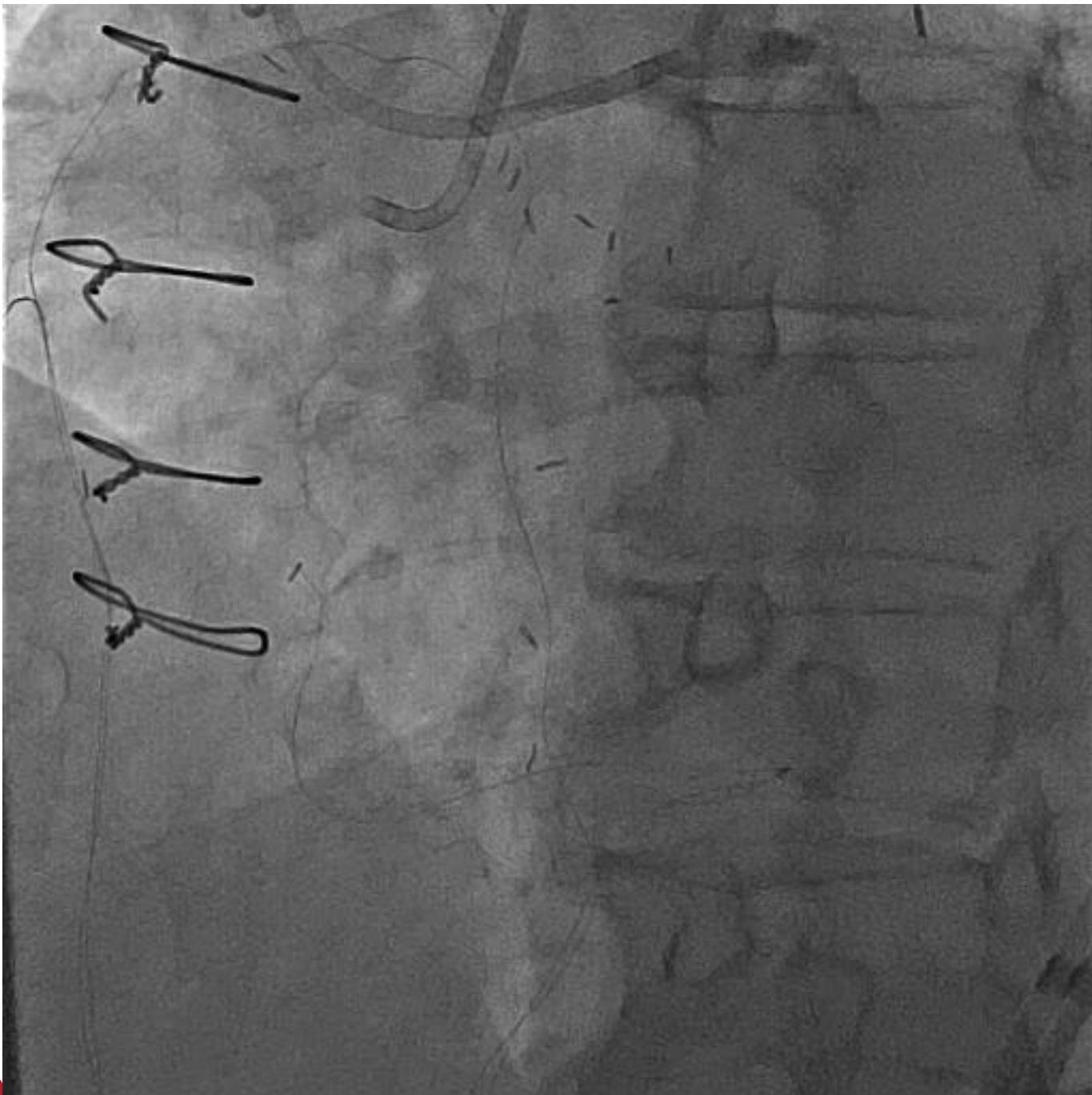

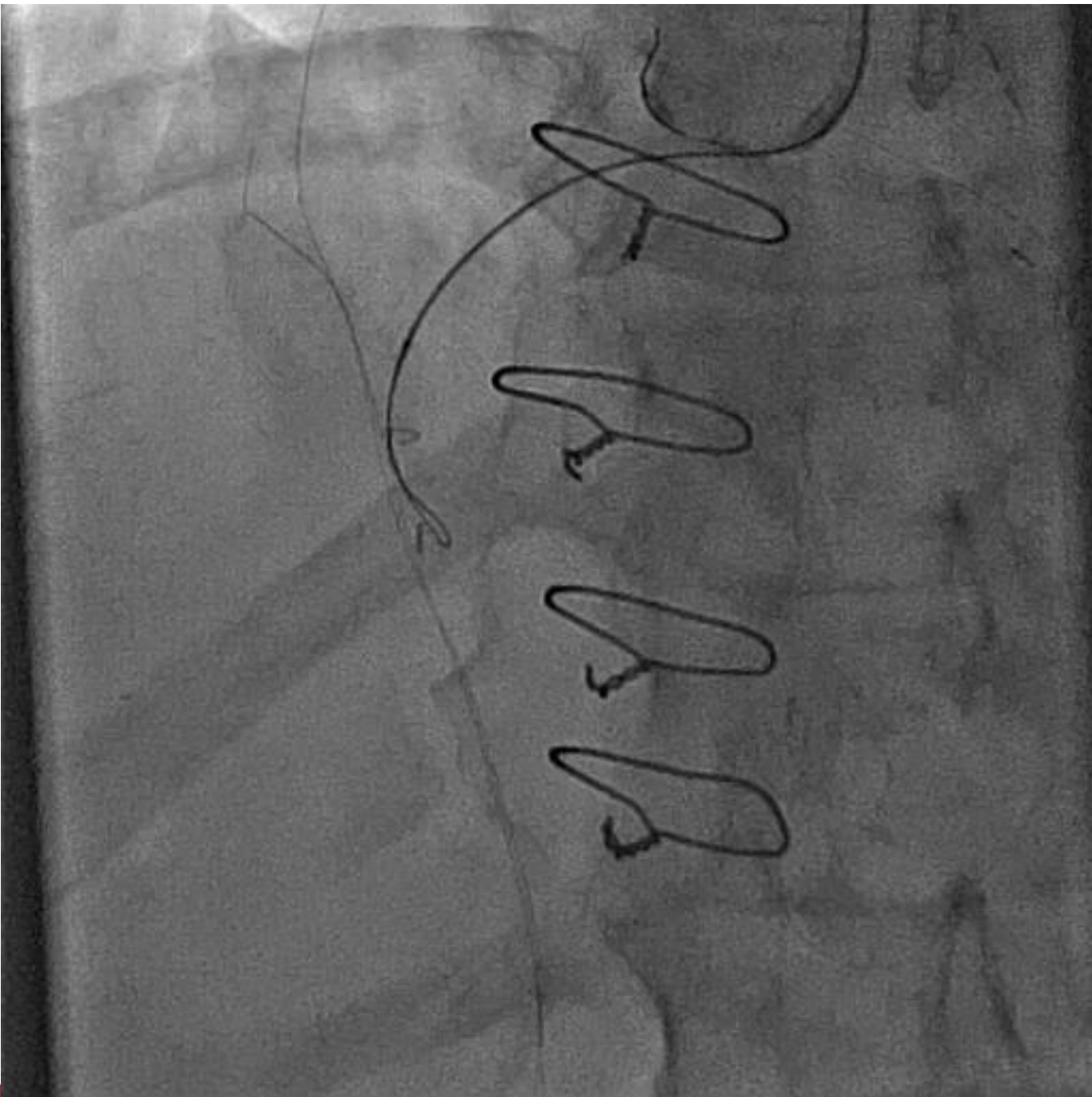
## Final Result

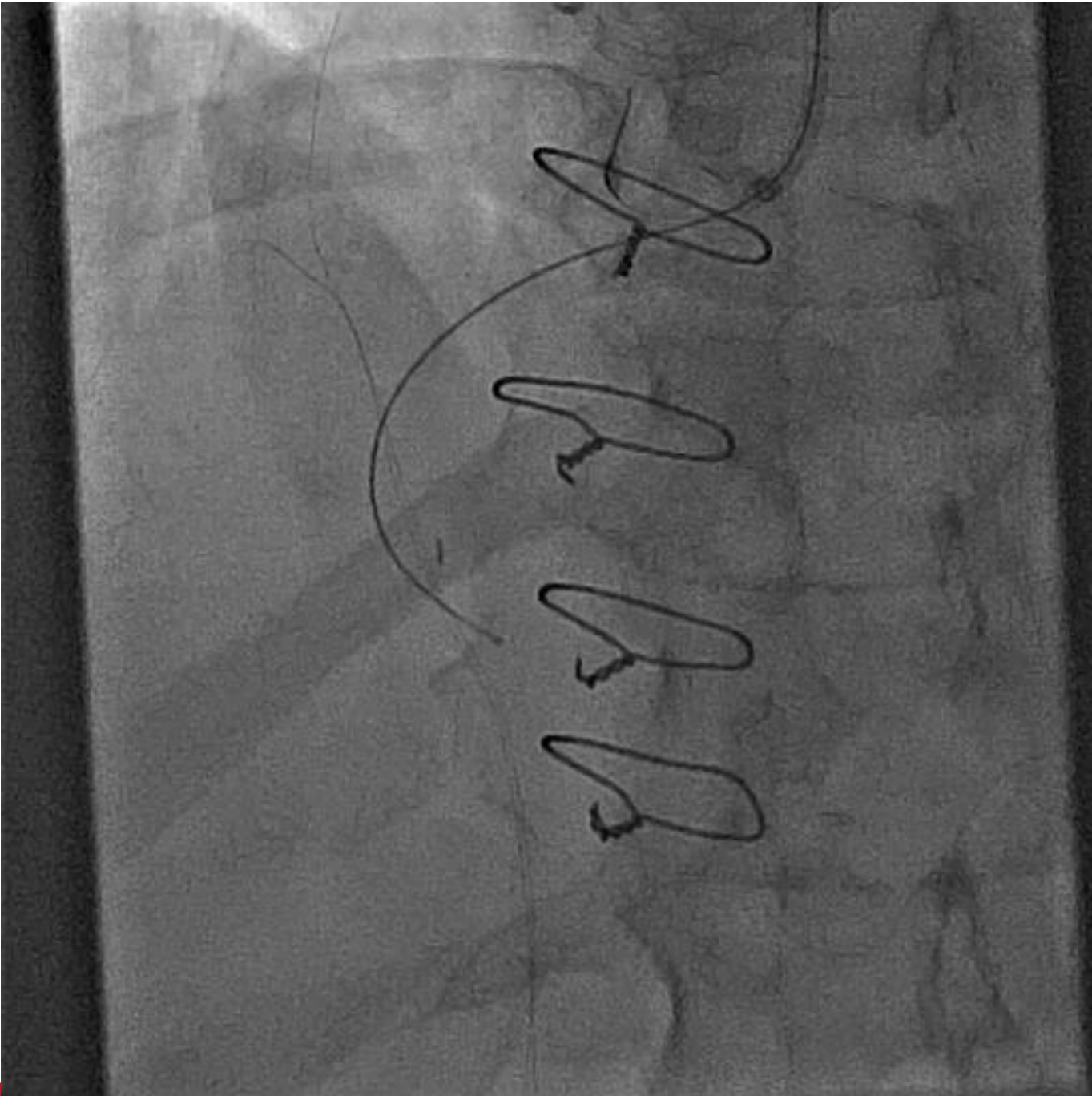

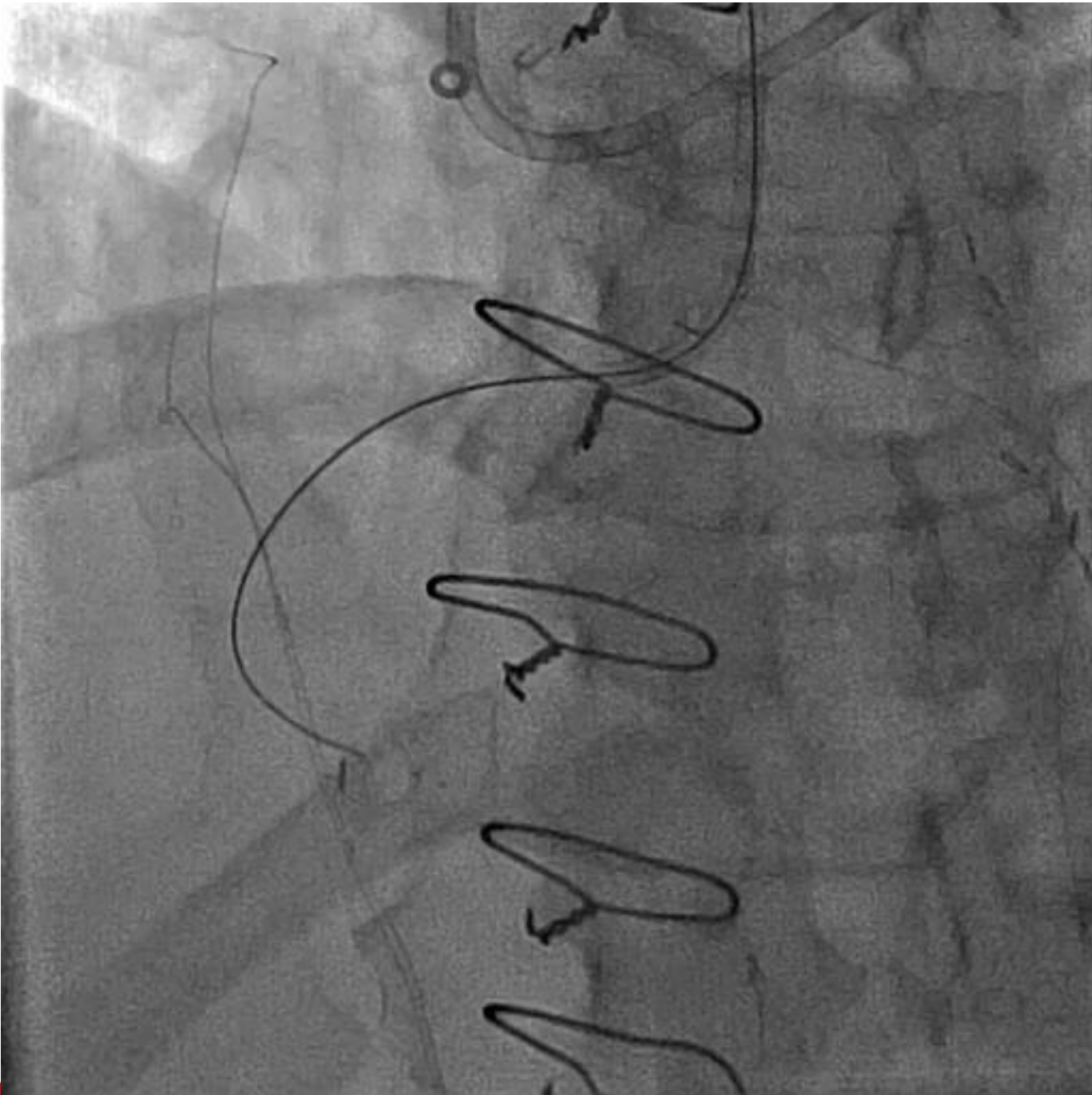# Antegrade Dissection Re-Entry (ADR)

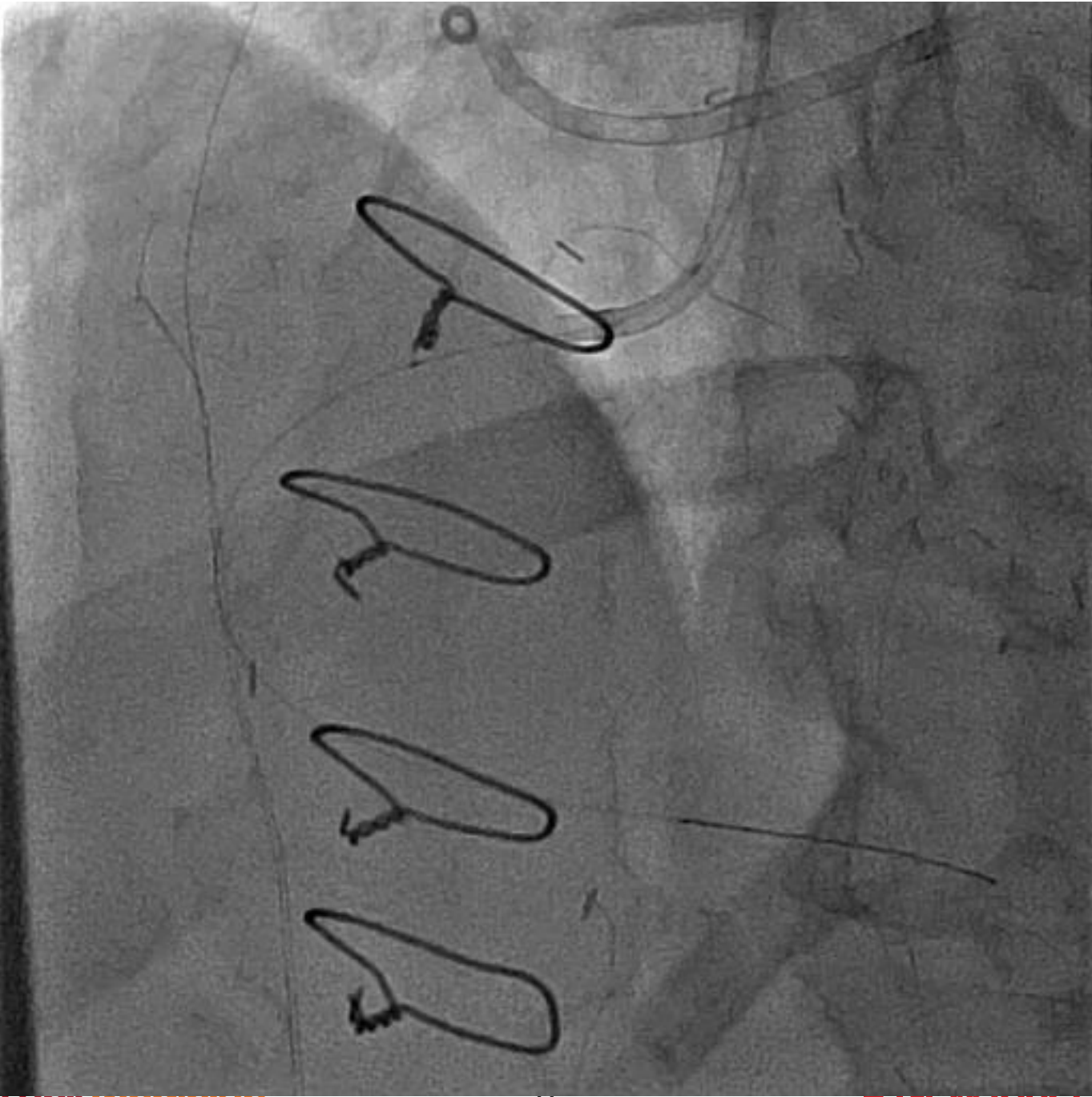


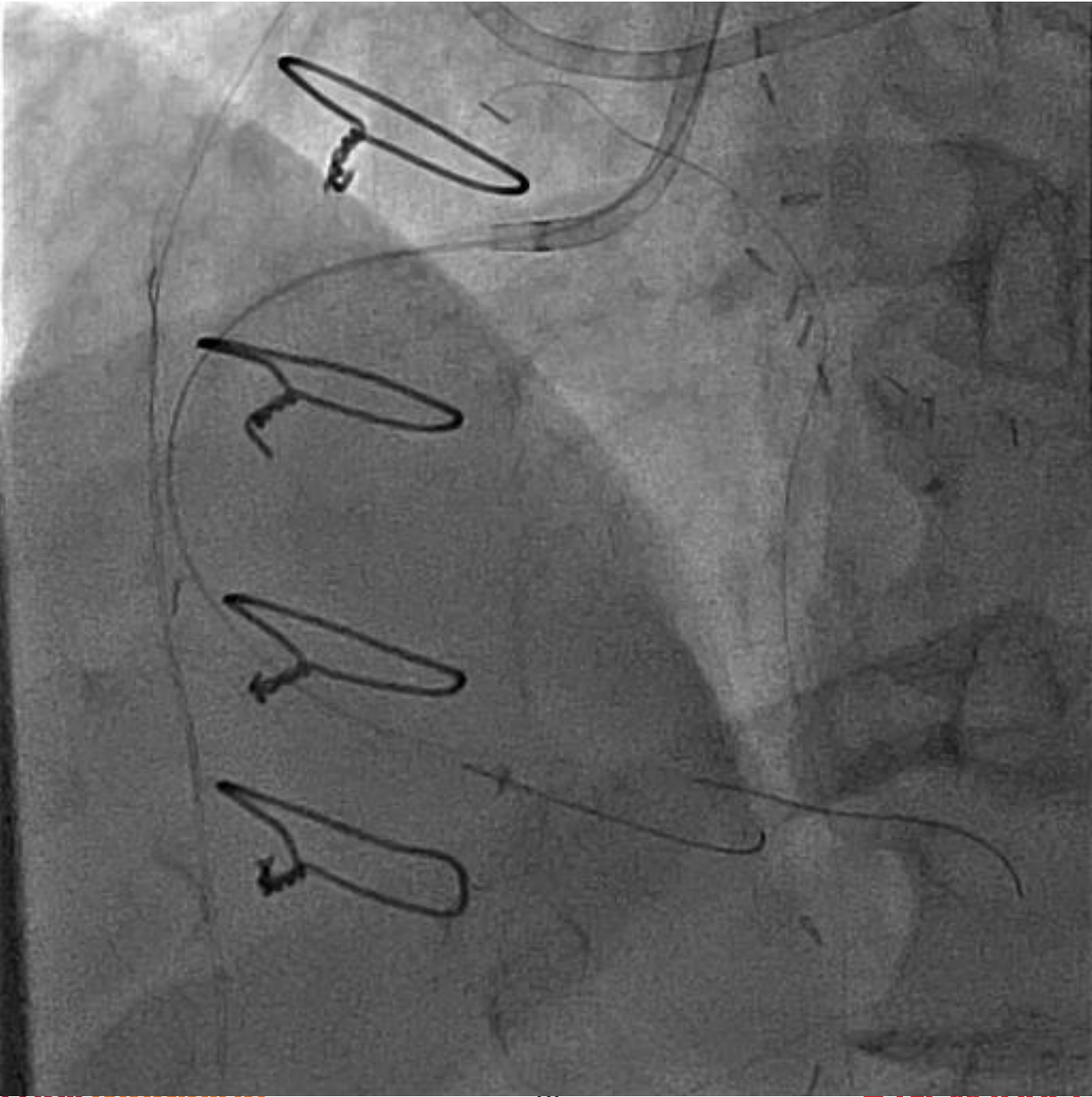
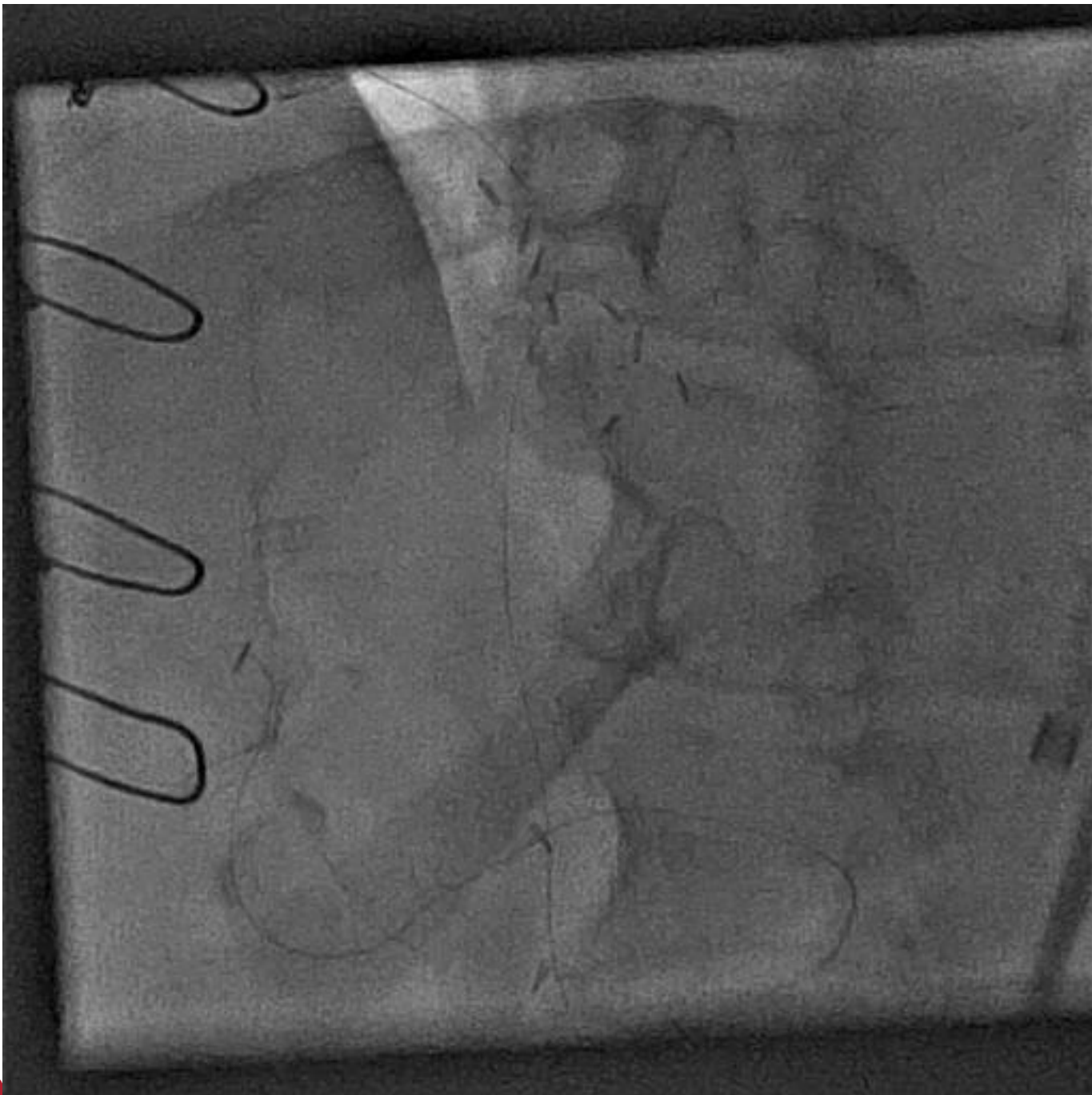













# STAR

## Subintimal Tracking And Re-entry

- Antegrade re-entry technique described by Antonio Columbo by entering the subintimal space with a knuckle wire and advancing the knuckled wire distally until it spontaneously re-enters the distal true lumen

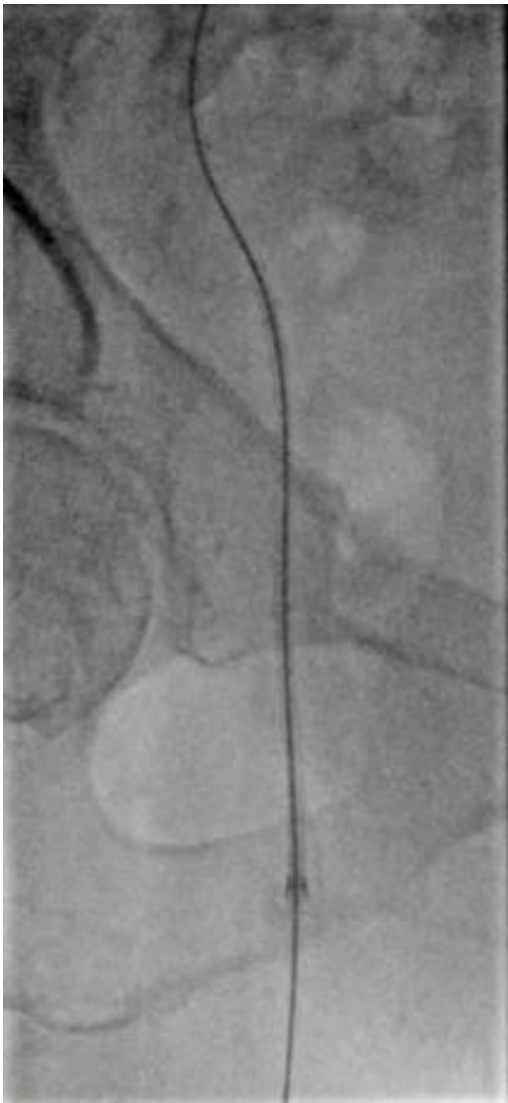


CTO-rPDA

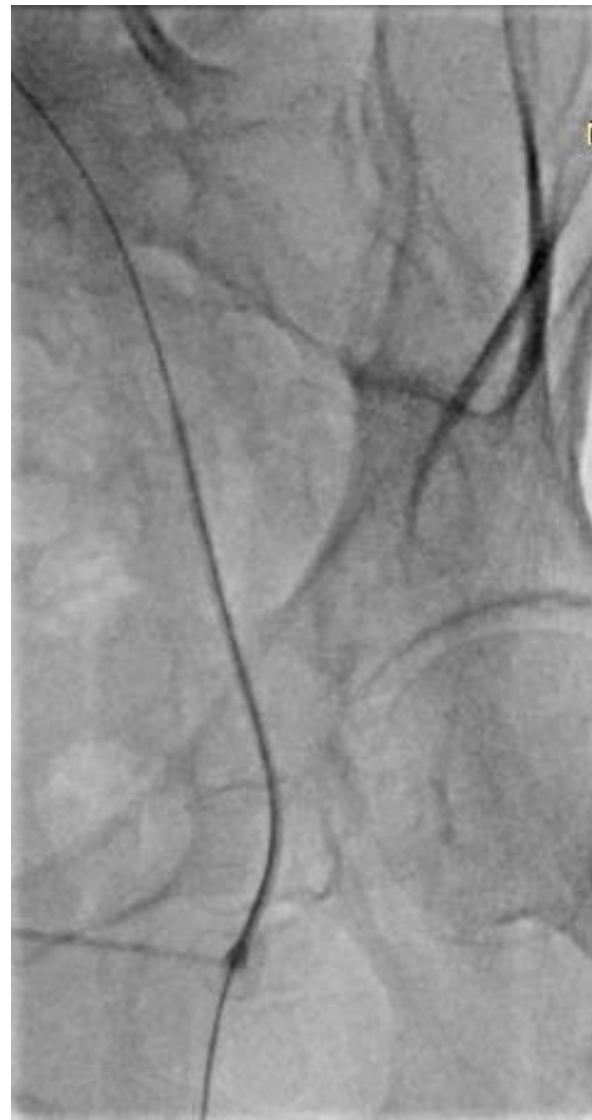# RETROGRADE TRUE TO TRUE



# Access



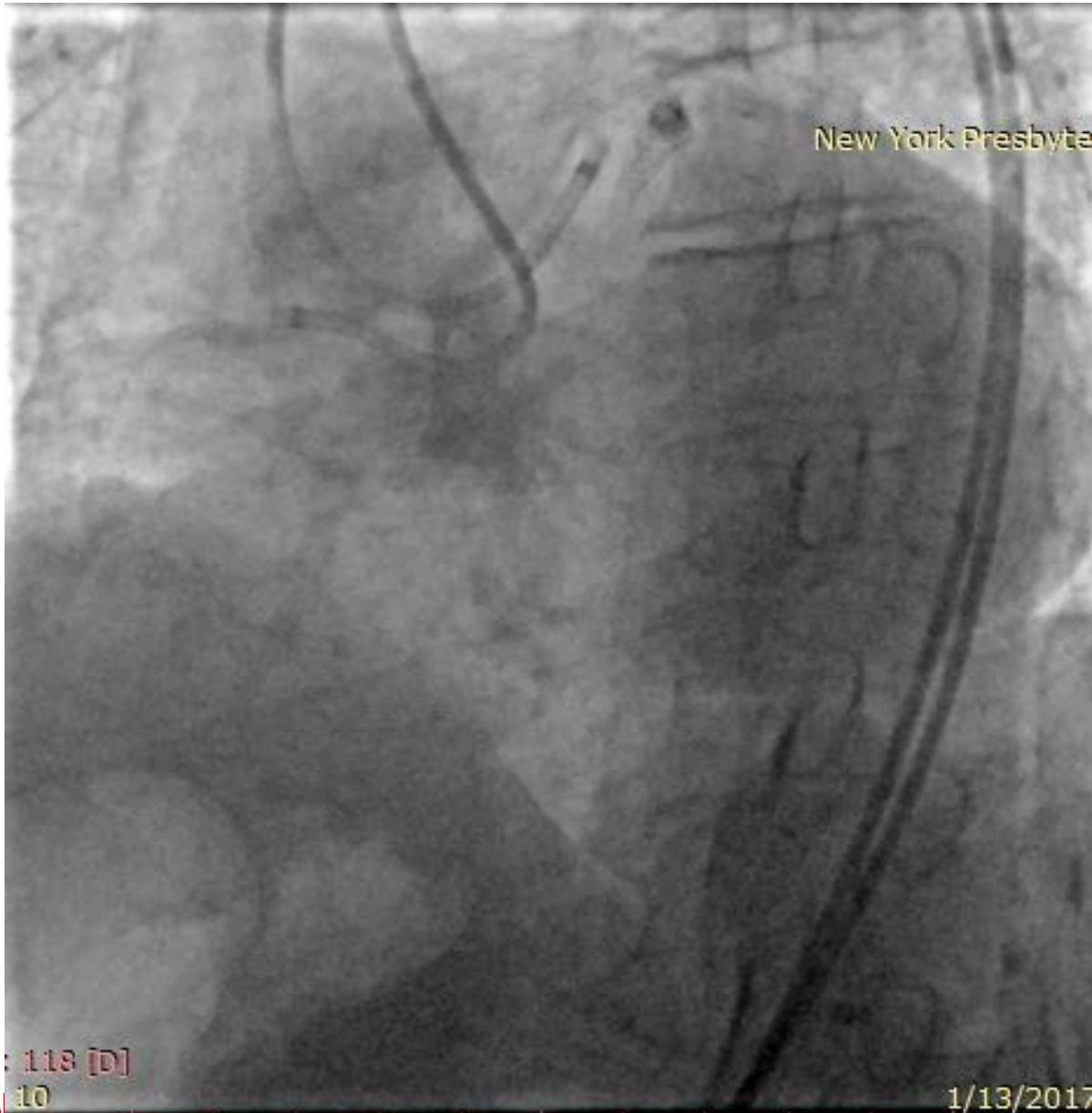7Fr RFA Long Sheath



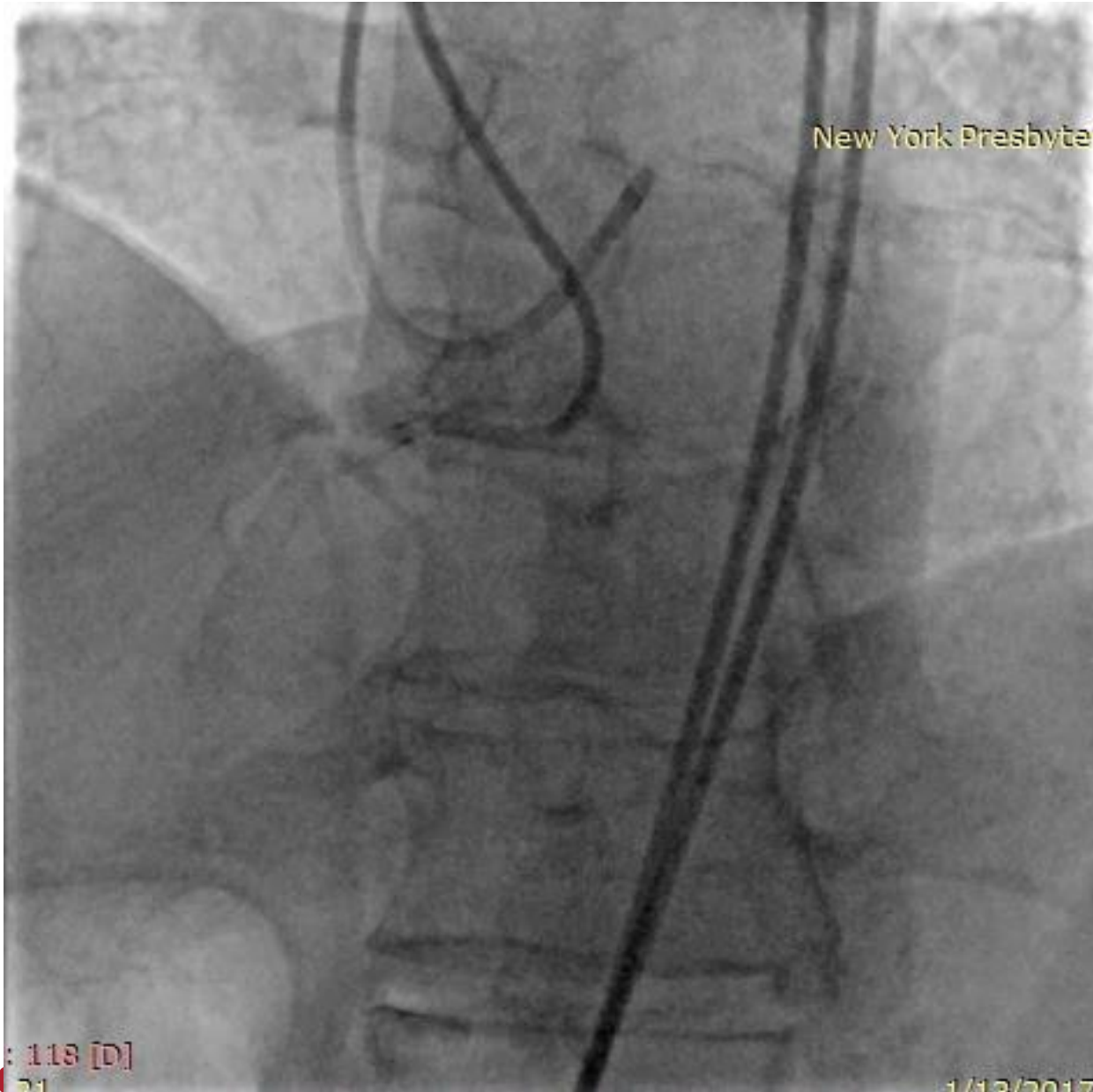7Fr LFA Long Sheath



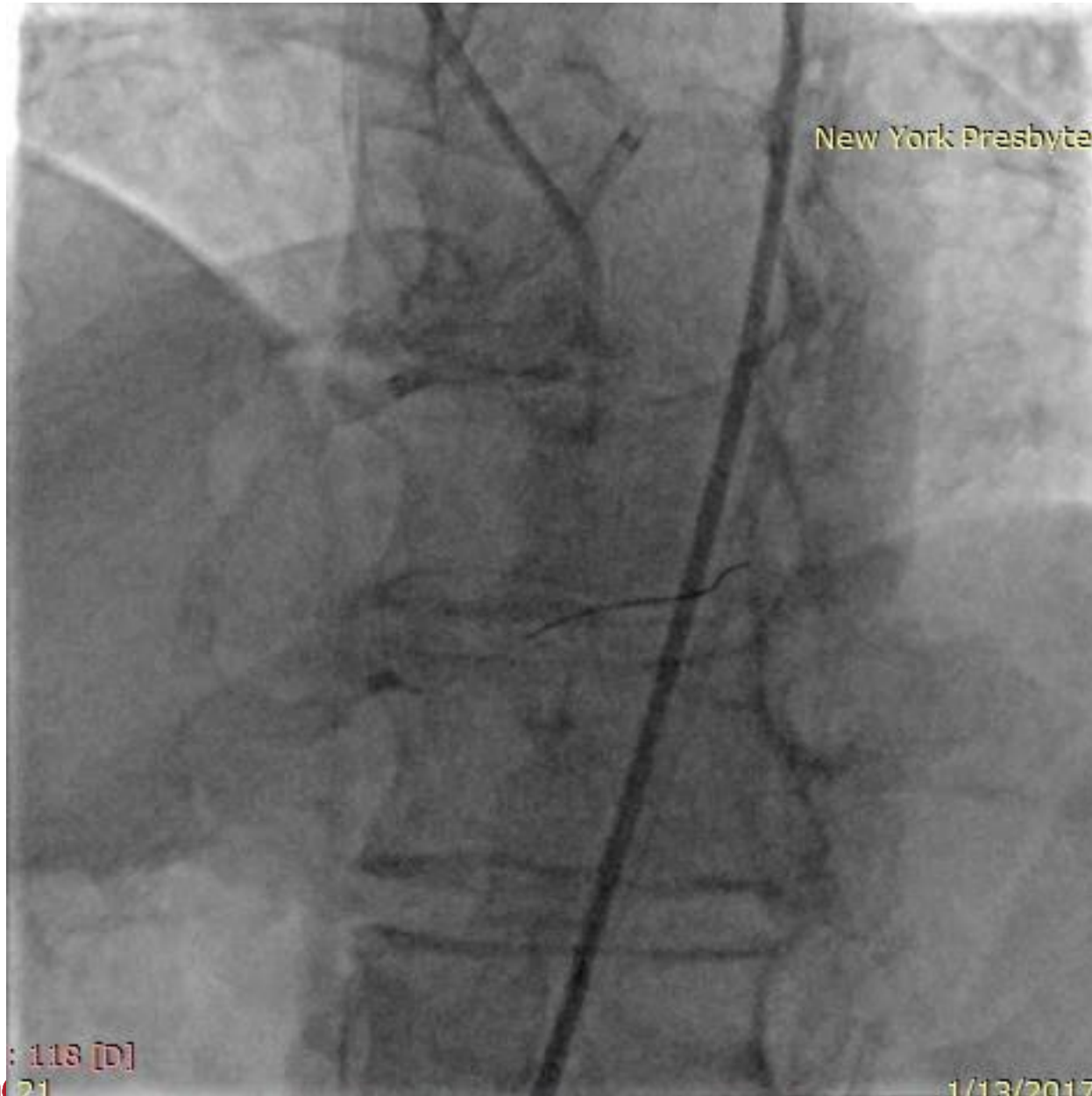
# Dual Injections



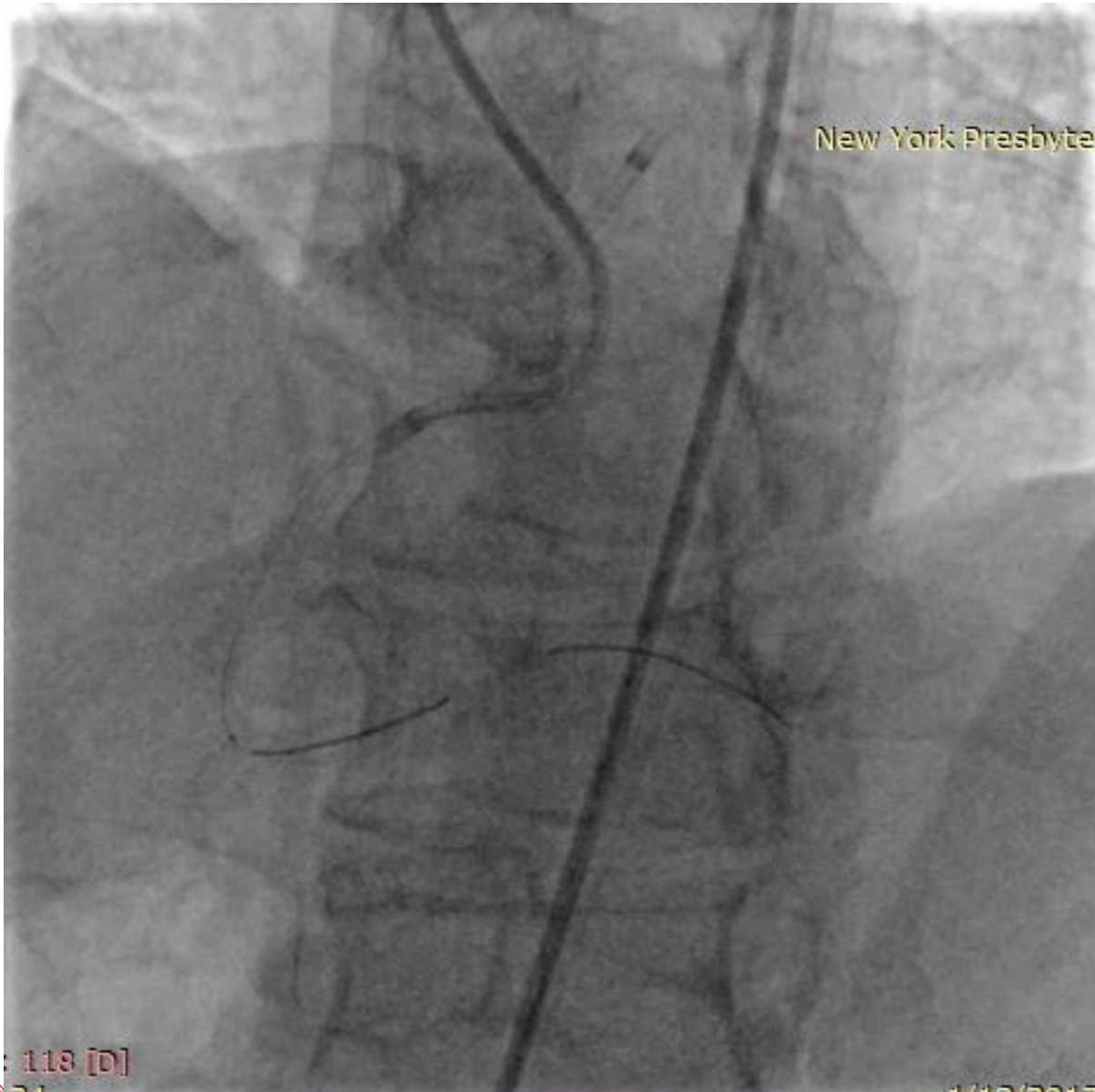
# Dual Injections



# Dual Injections



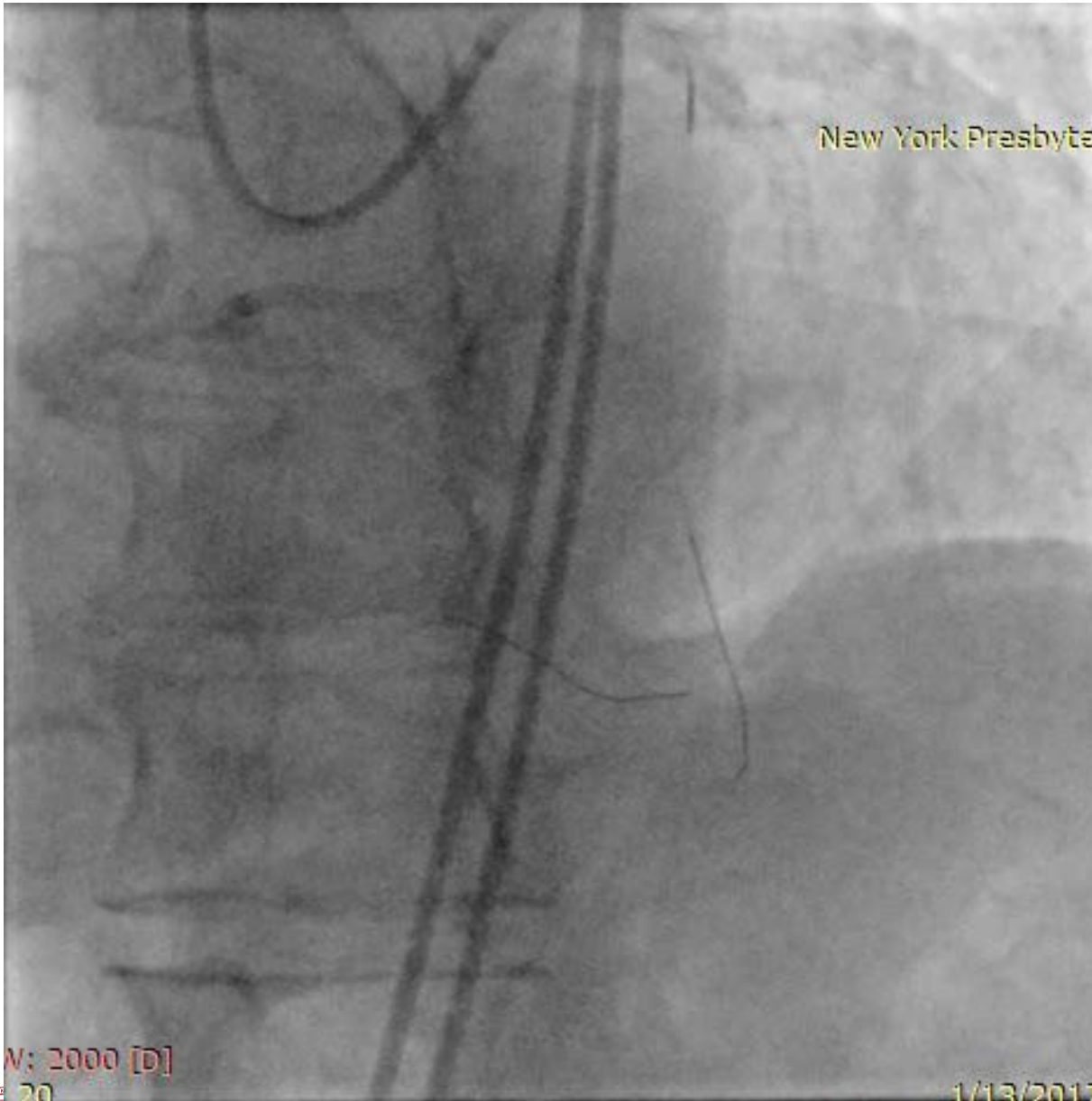
# Antegrade Wire Escalation



**Fine Cross 130cm**



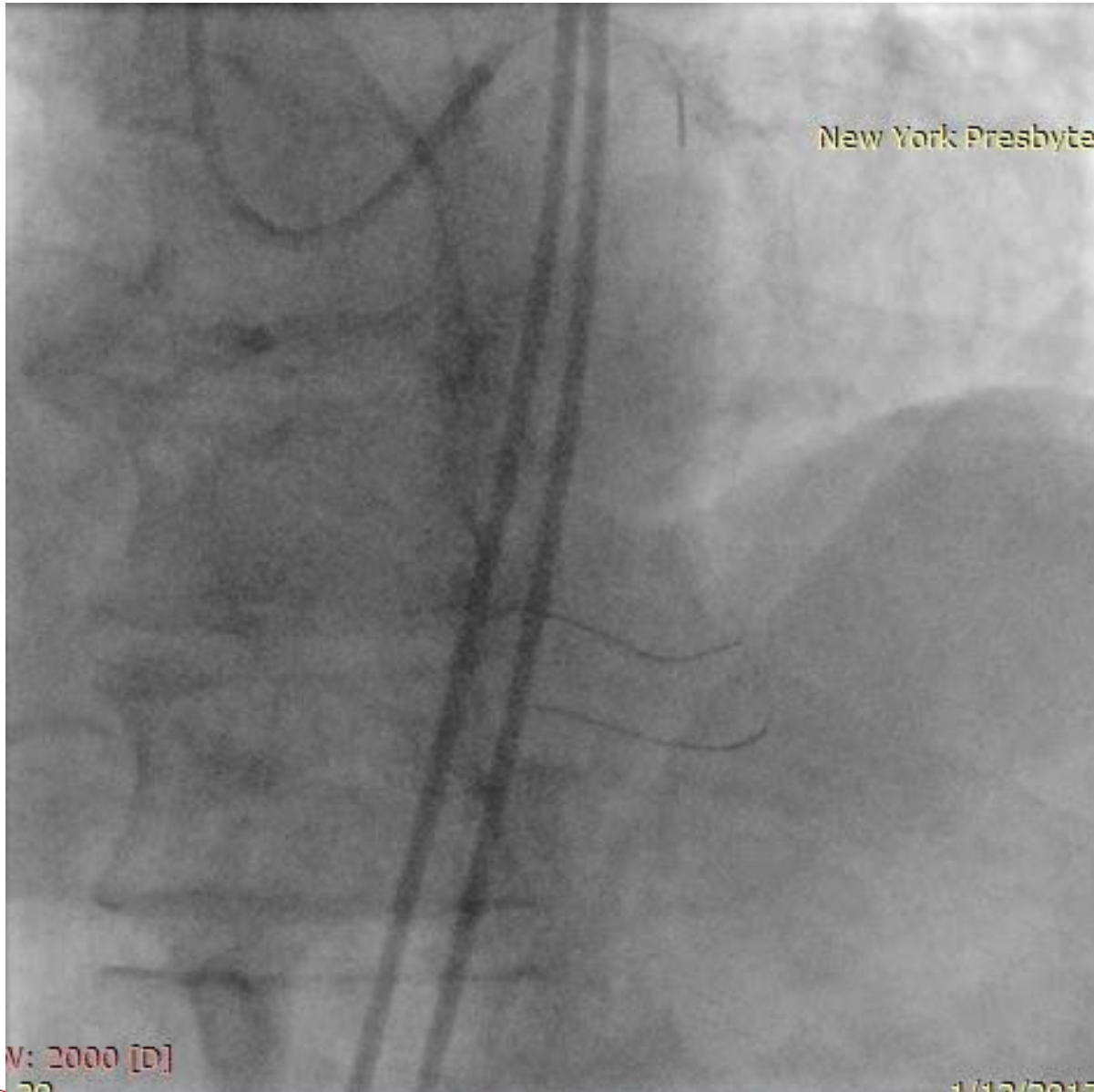
# Retrograde via LAD Septals



TurnPike LP 150cm



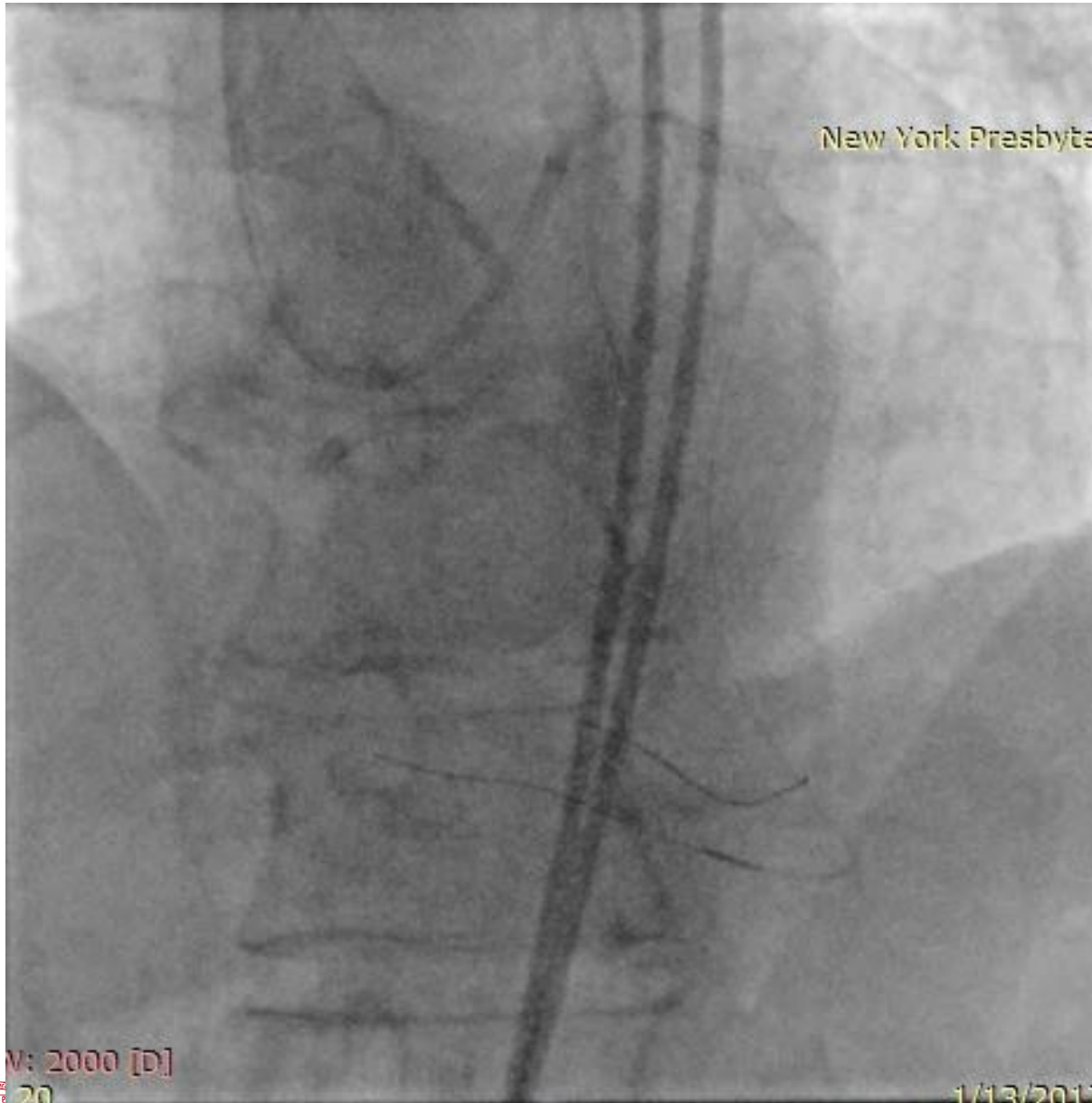# Retrograde via LAD Septals



TurnPike LP 150cm

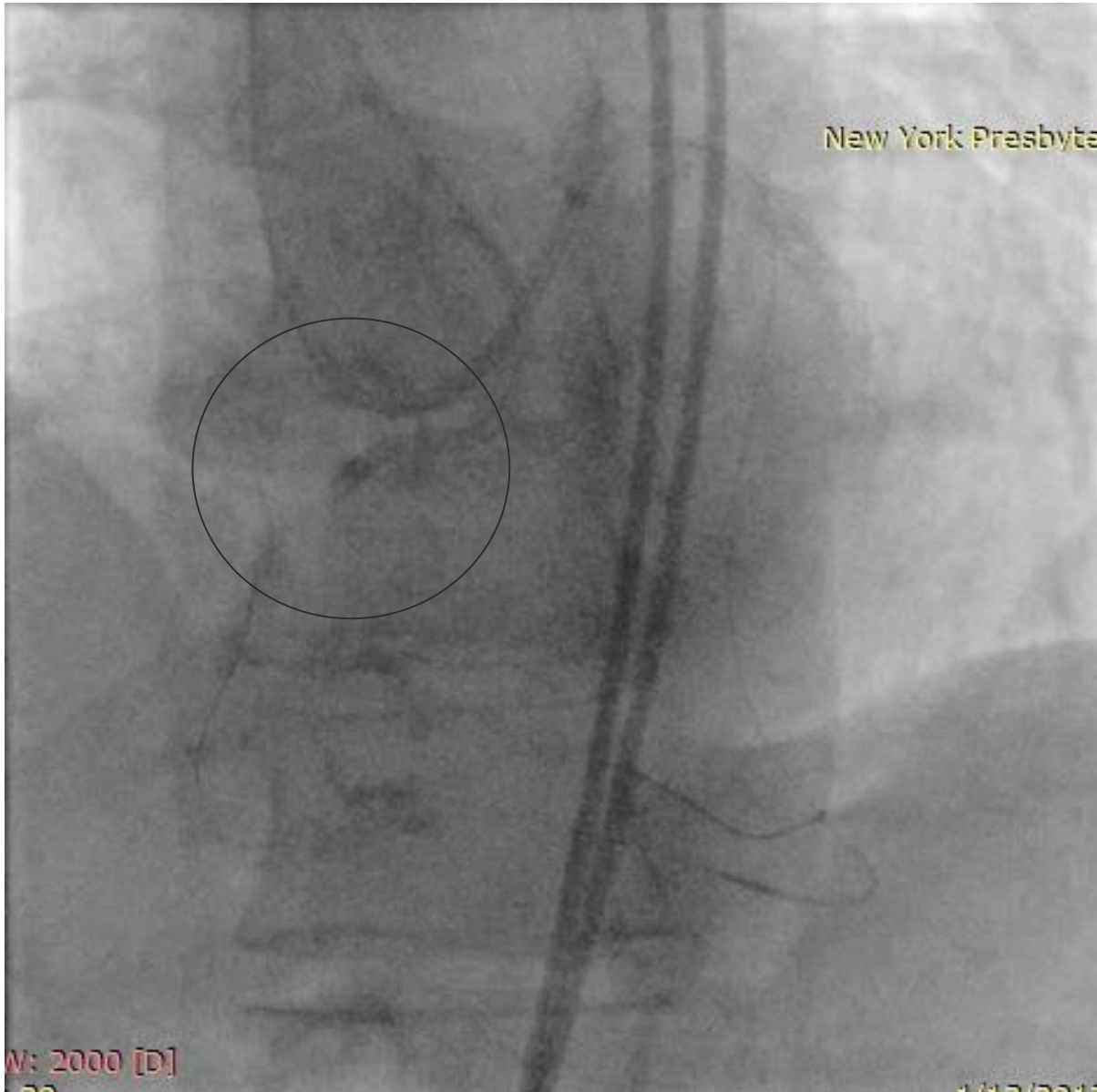


# Retrograde True to True



TurnPike LP 150cm

# Retrograde True to True

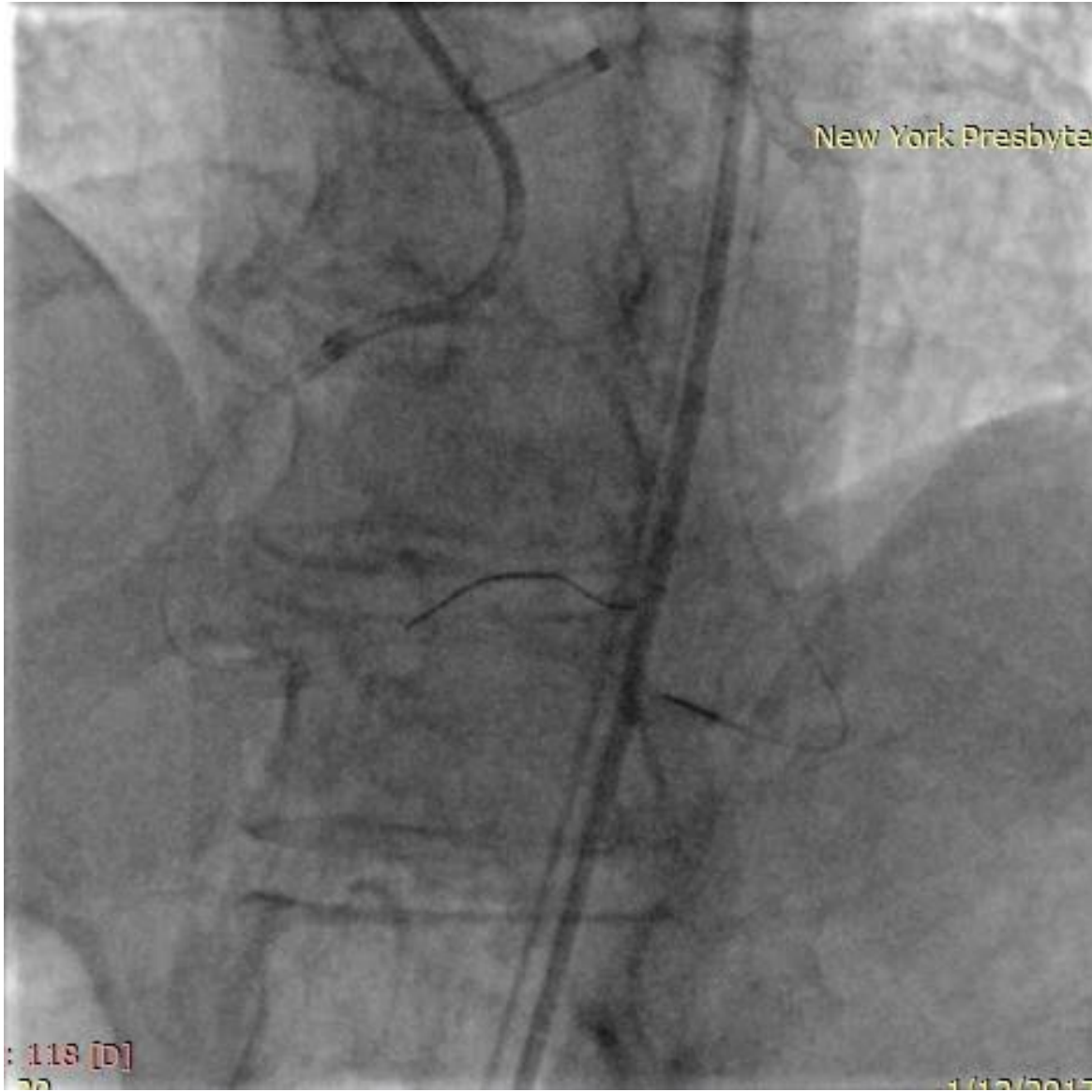

**Externalization**

**TurnPike LP 150cm**



# After Ballooning

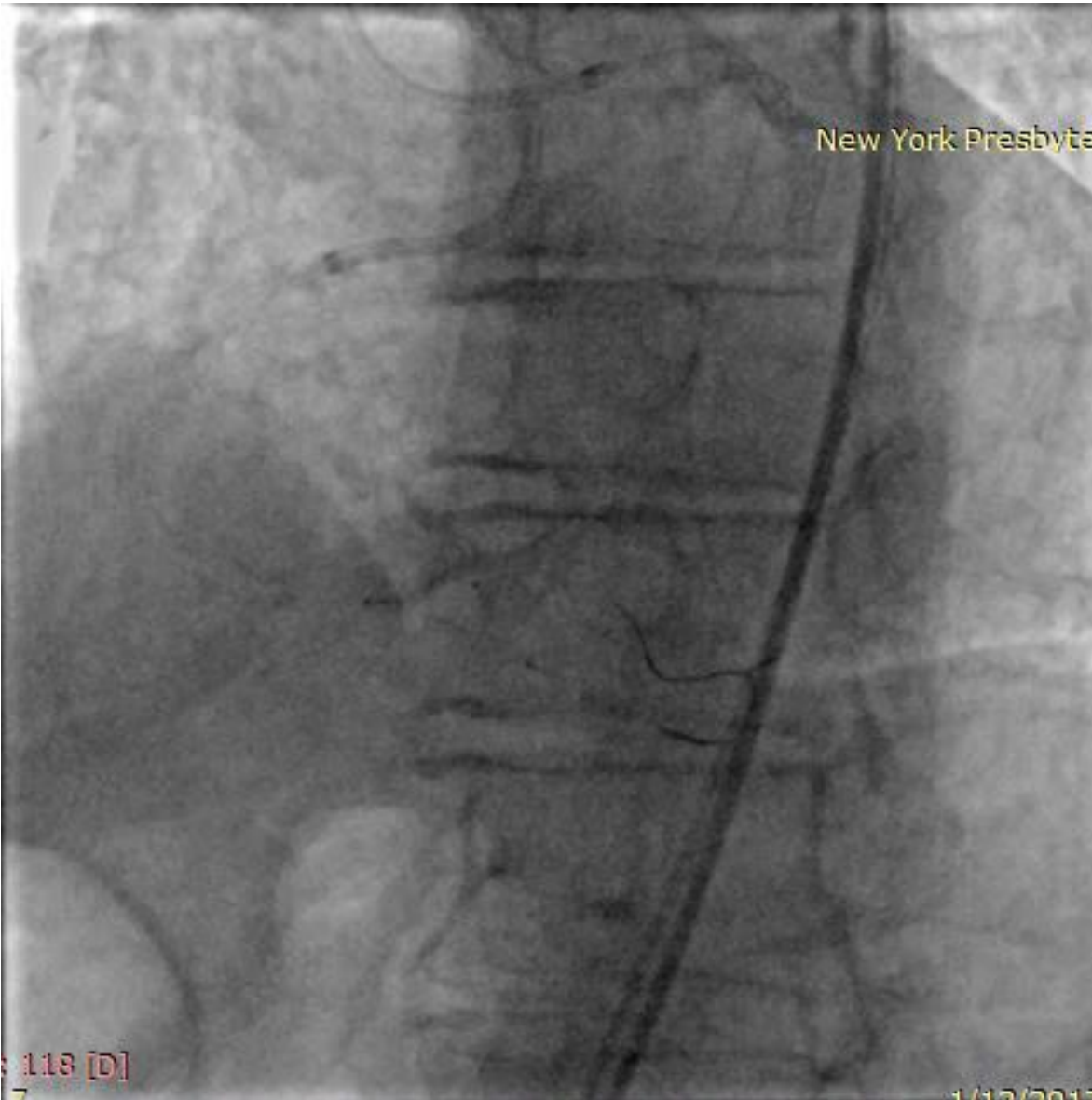


**RG3 Wire  
BMW in RPL**

**After Predilation with  
2.0 x 15 mm Balloon**



# Kissing Pre Dilation

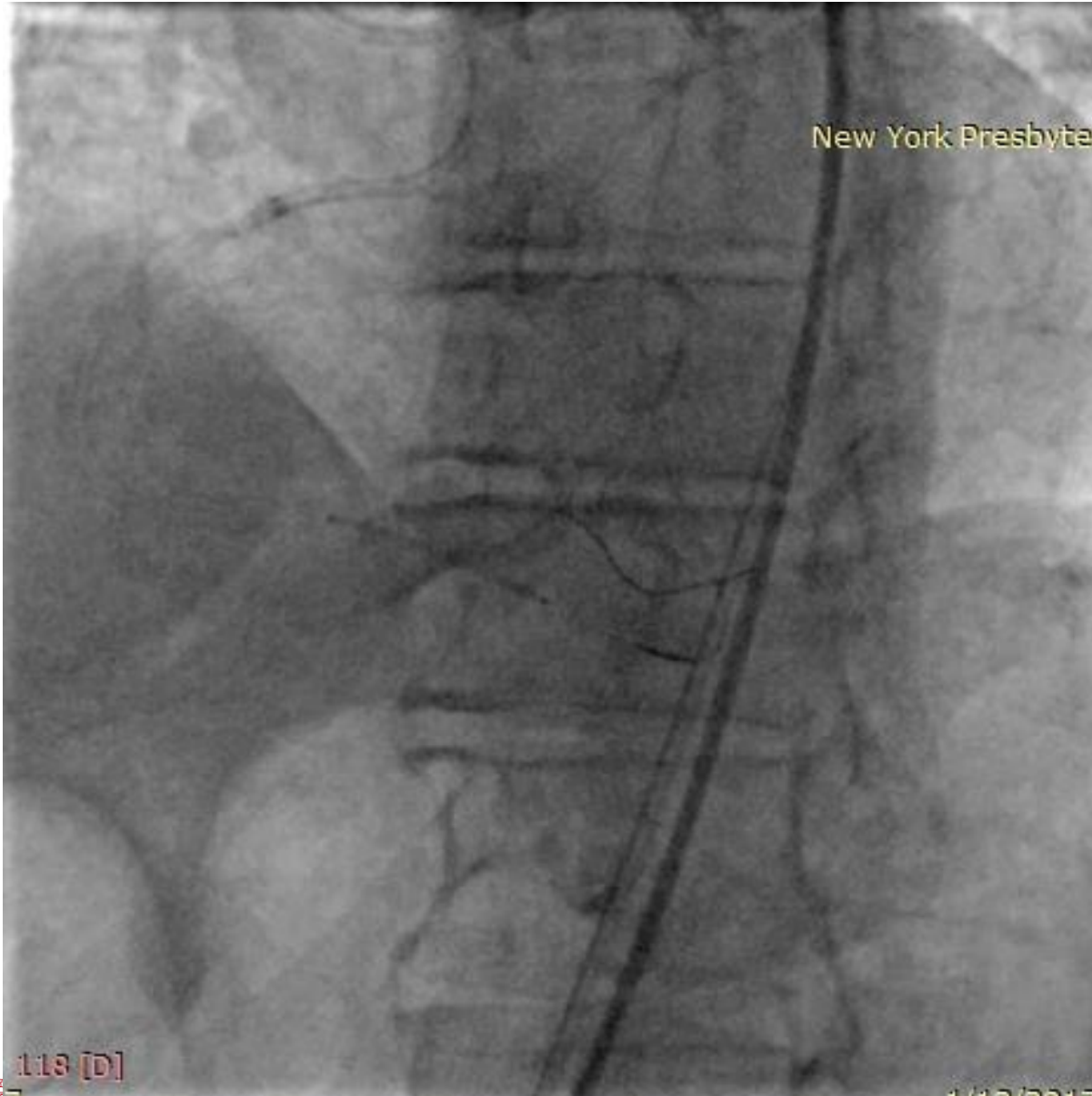


**RG3 Wire  
BMW in RPL**

**NC 3.0 x 20  
NC 3.0 x 20**



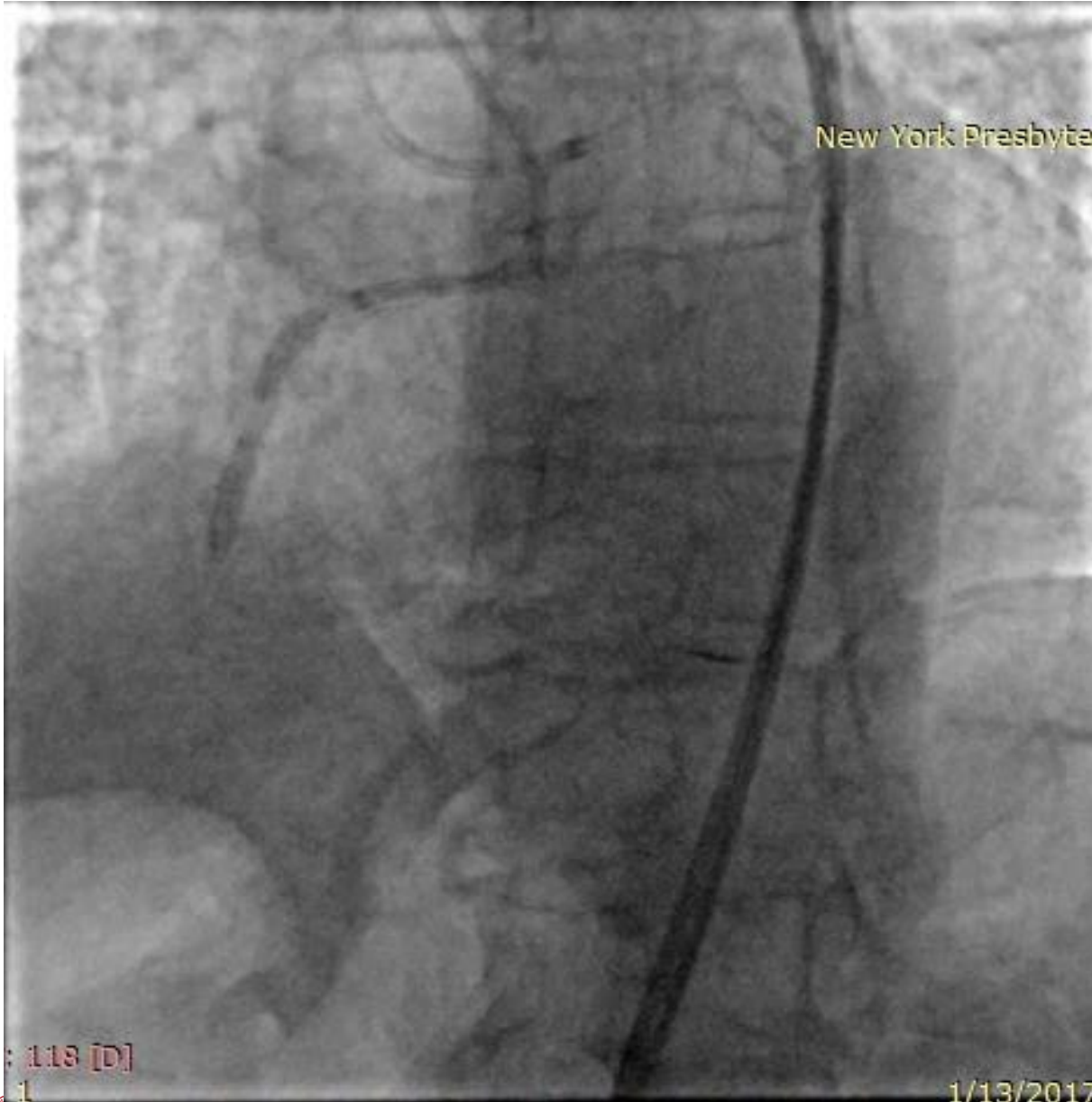# IVUS Guided Provisional Stenting



**RG3 Wire  
BMW in RPL**

**PDA: DES 3.0 X 26 mm**

# IVUS Guided PCI-pRCA

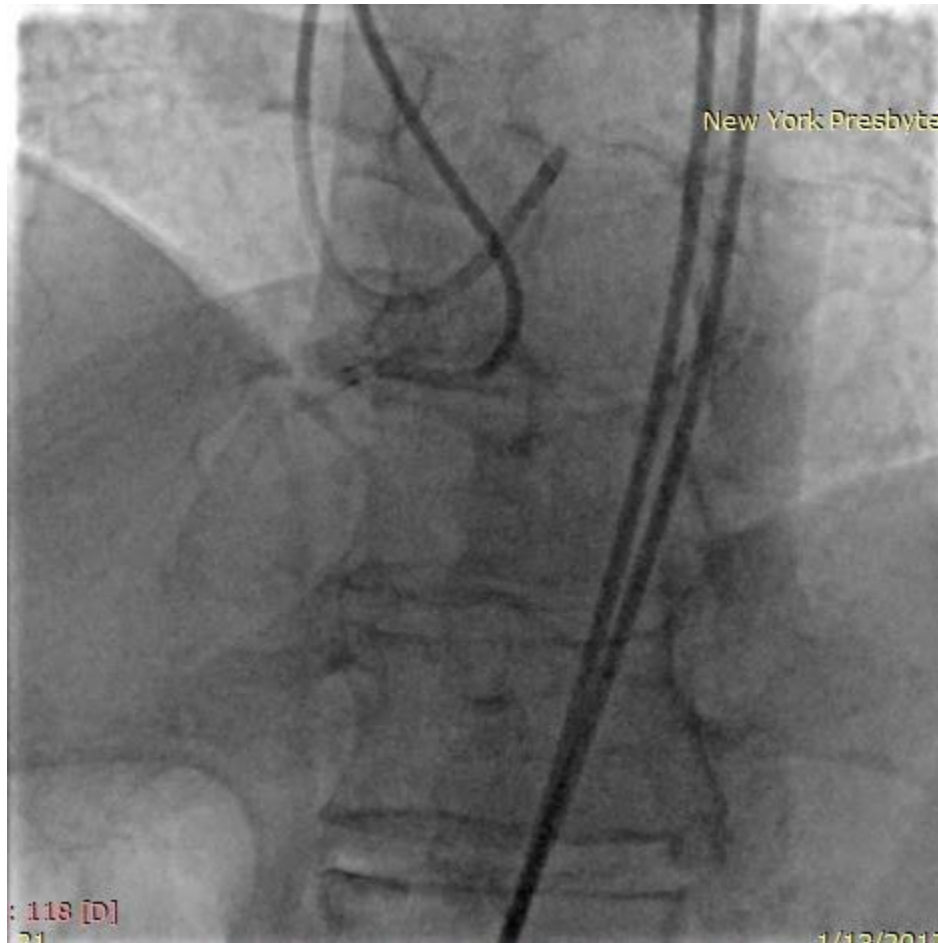

**RG3 Wire**

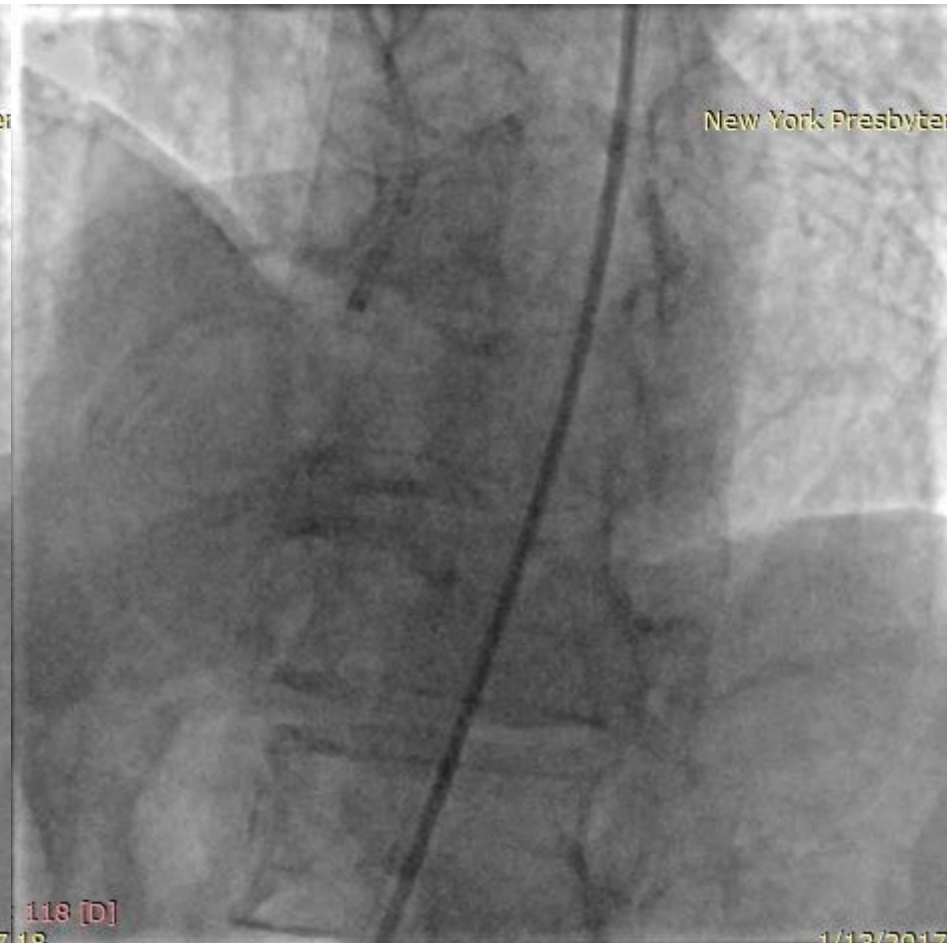**pRCA: DES 4.0 X 34 mm**



# Final Results



Pre



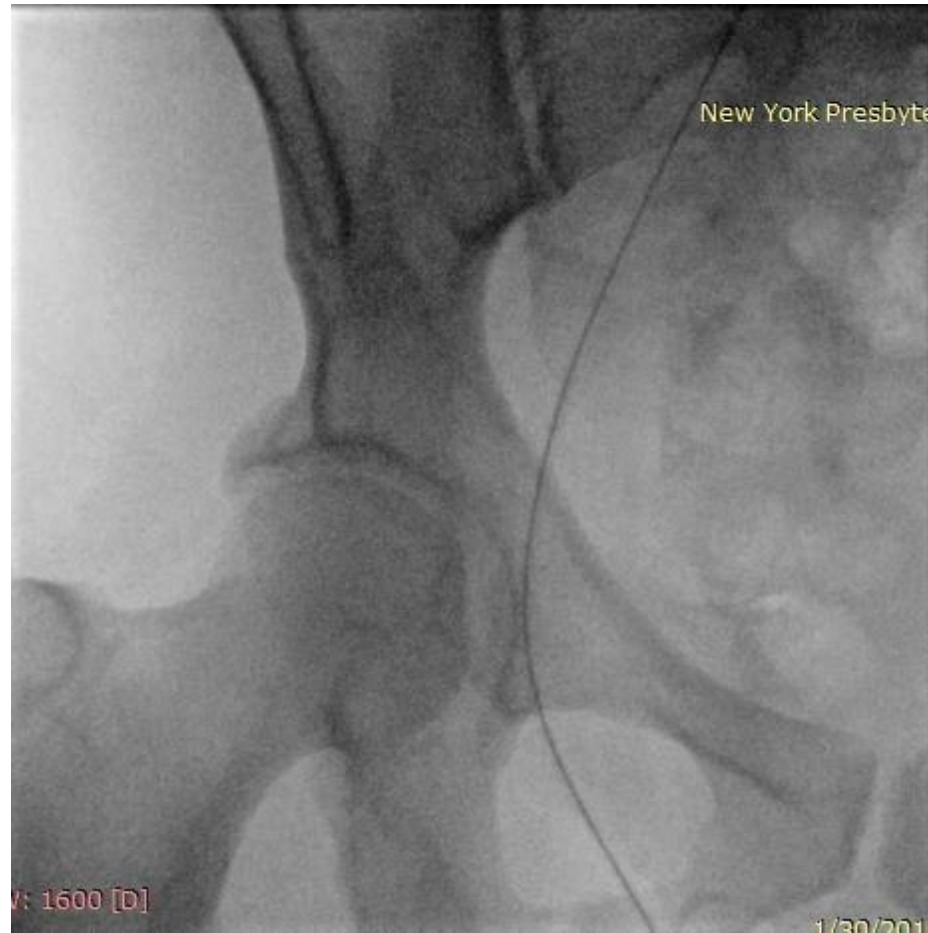Post

CTO-RCA

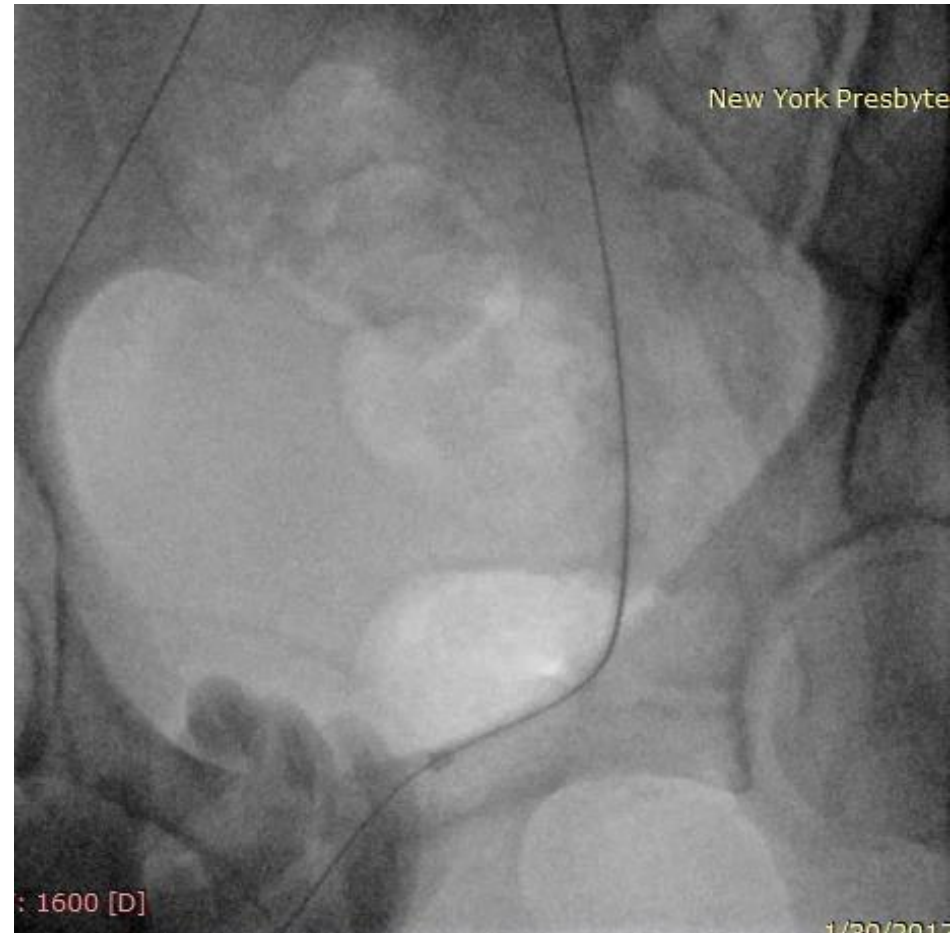# RETROGRADE REVERSE CART



# Access

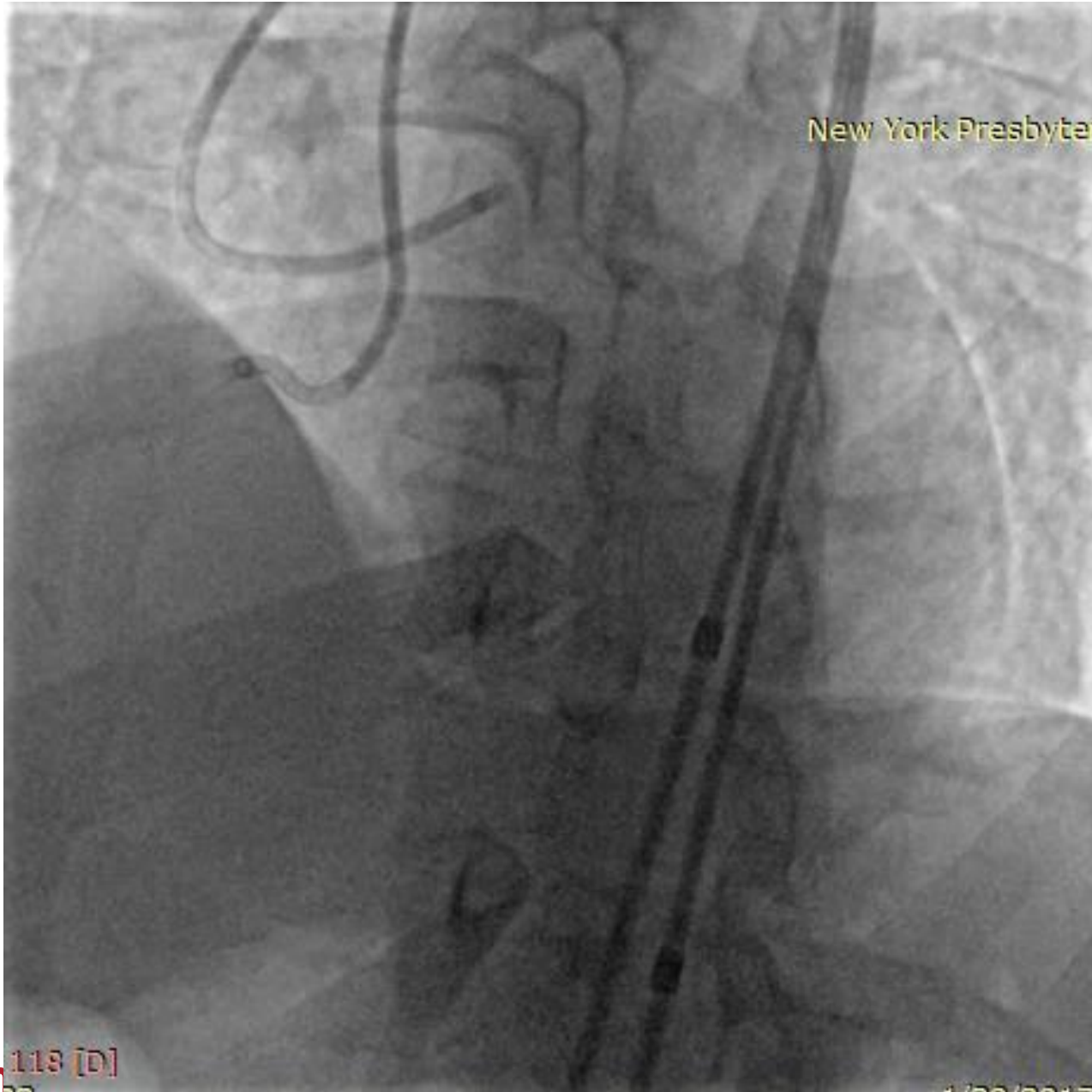


**8Fr RFA Long Sheath  
8Fr EBU 3.75 90cm**

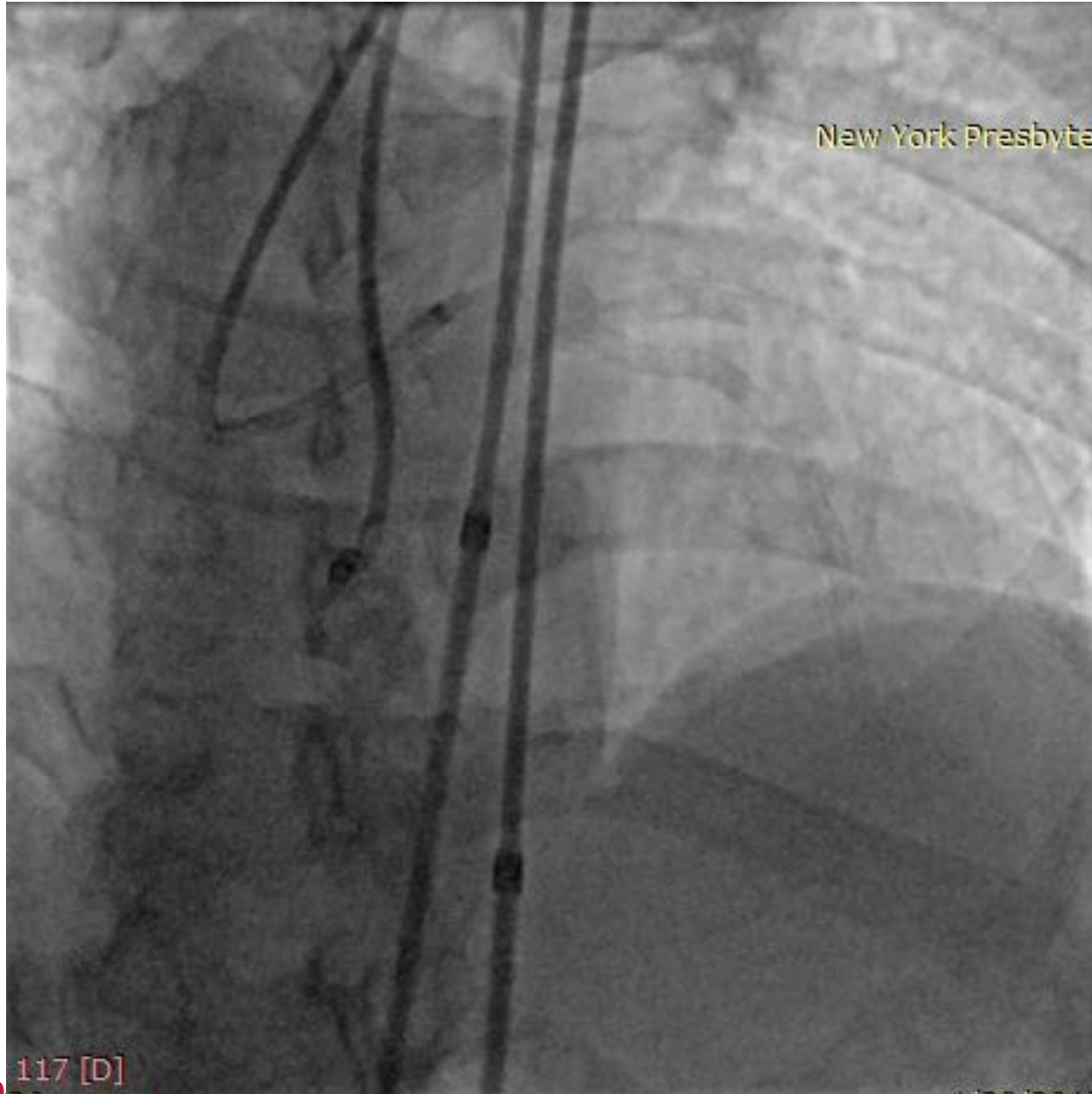


**8Fr LFA Long Sheath  
8Fr AL1.0 SH 90cm**

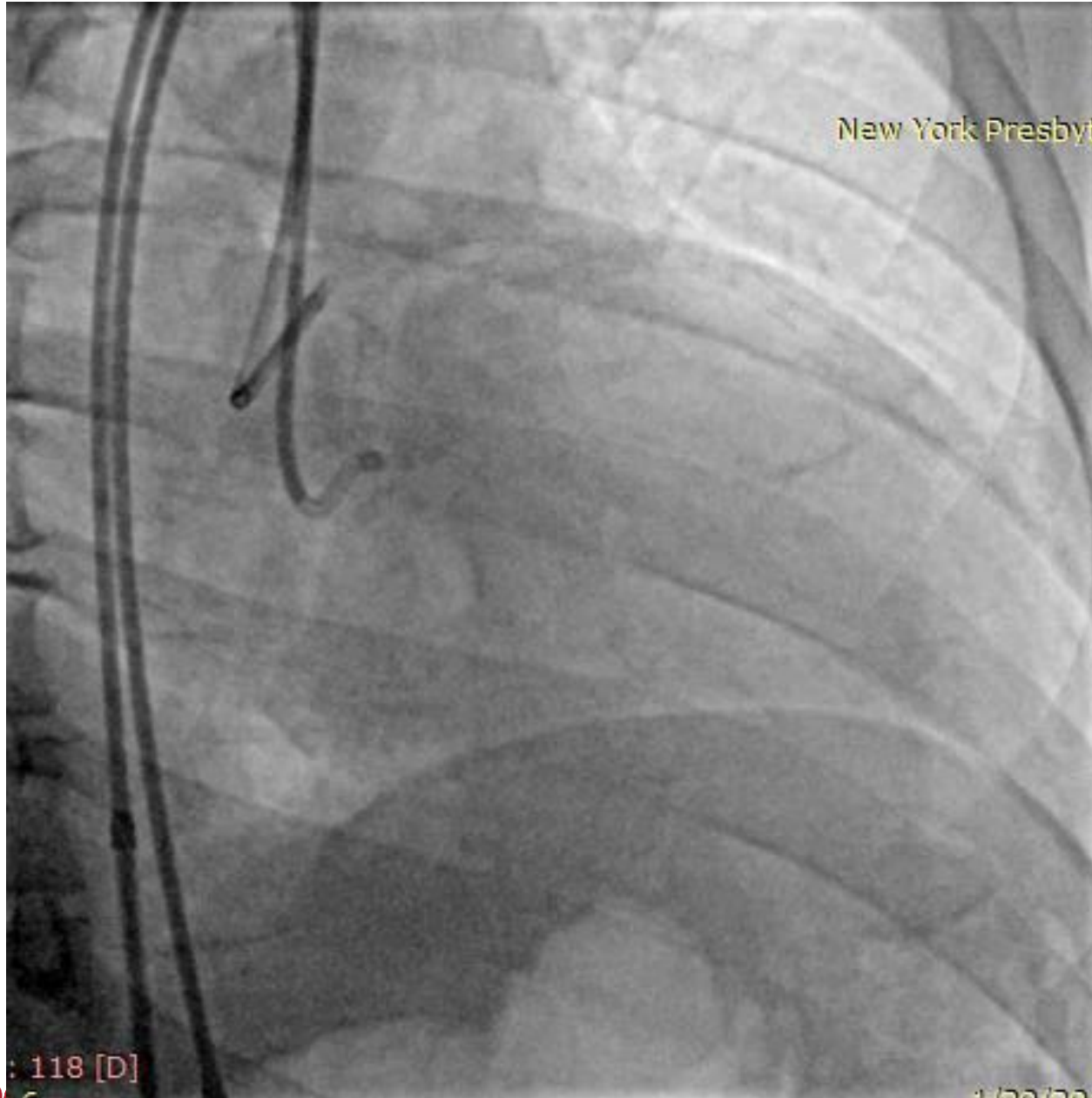
# Dual Injections



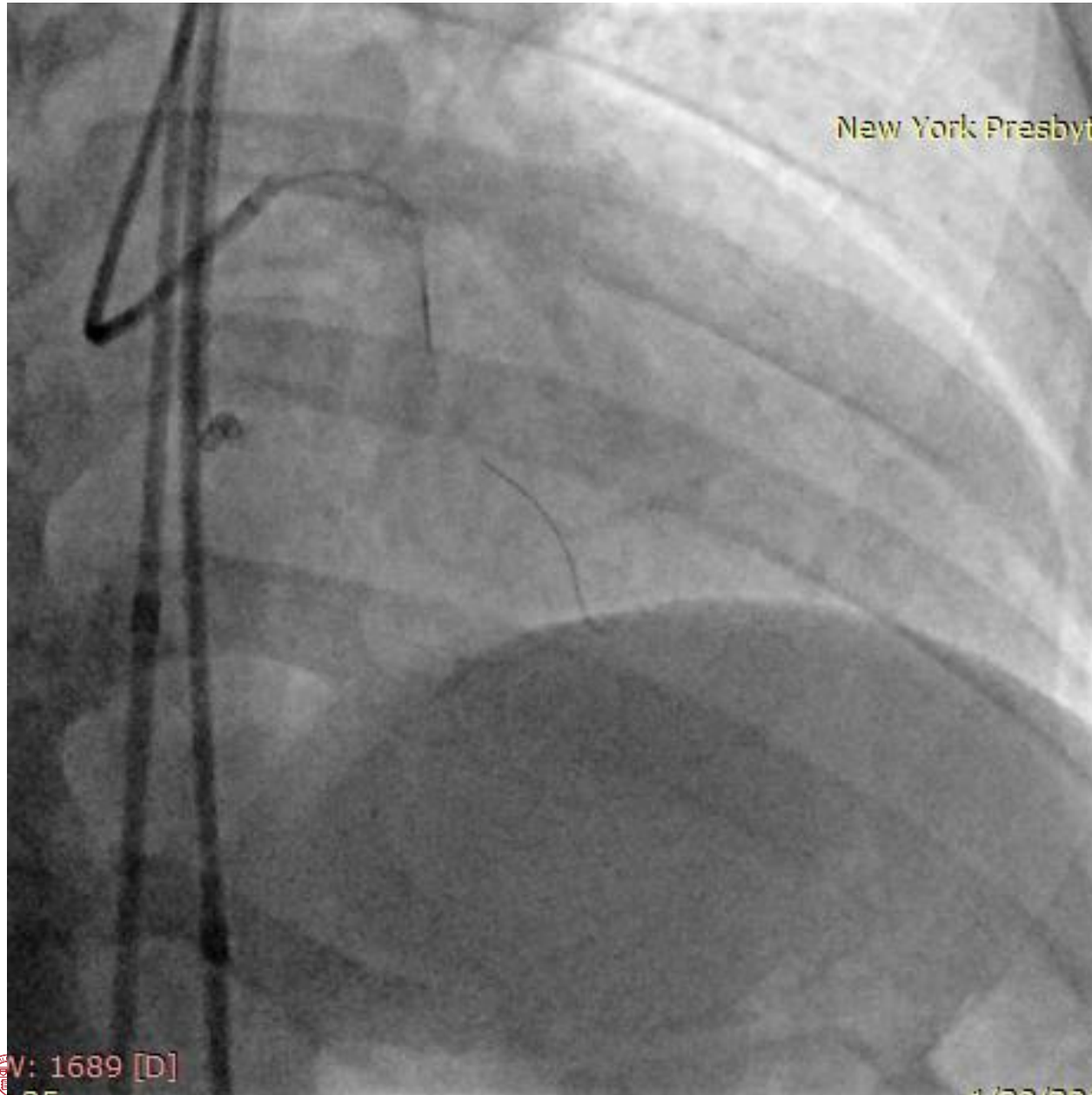
# Dual Injections



# Dual Injections



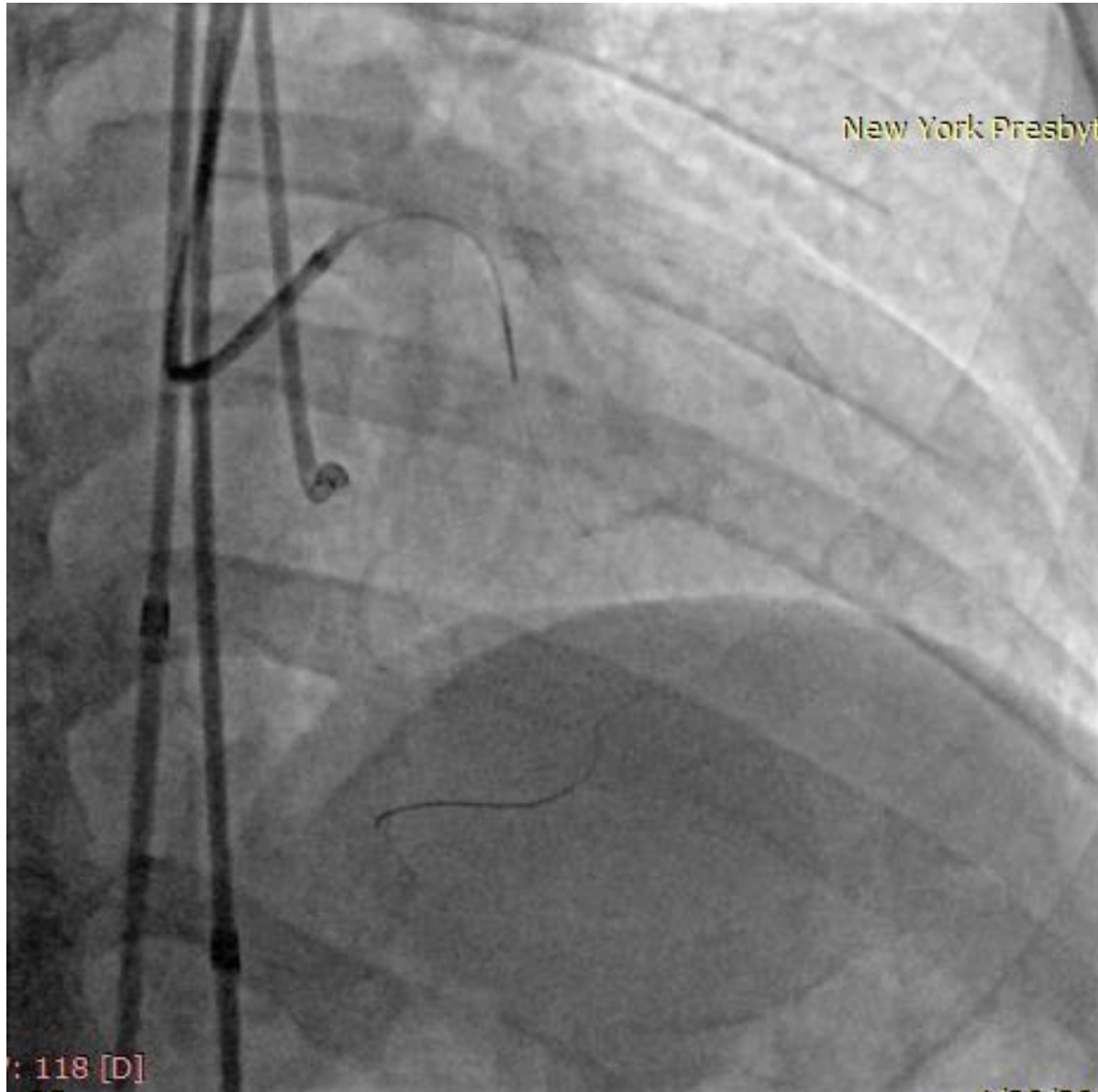
# Retrograde via LAD Septals



New York Presbyte

TurnPike 150cm

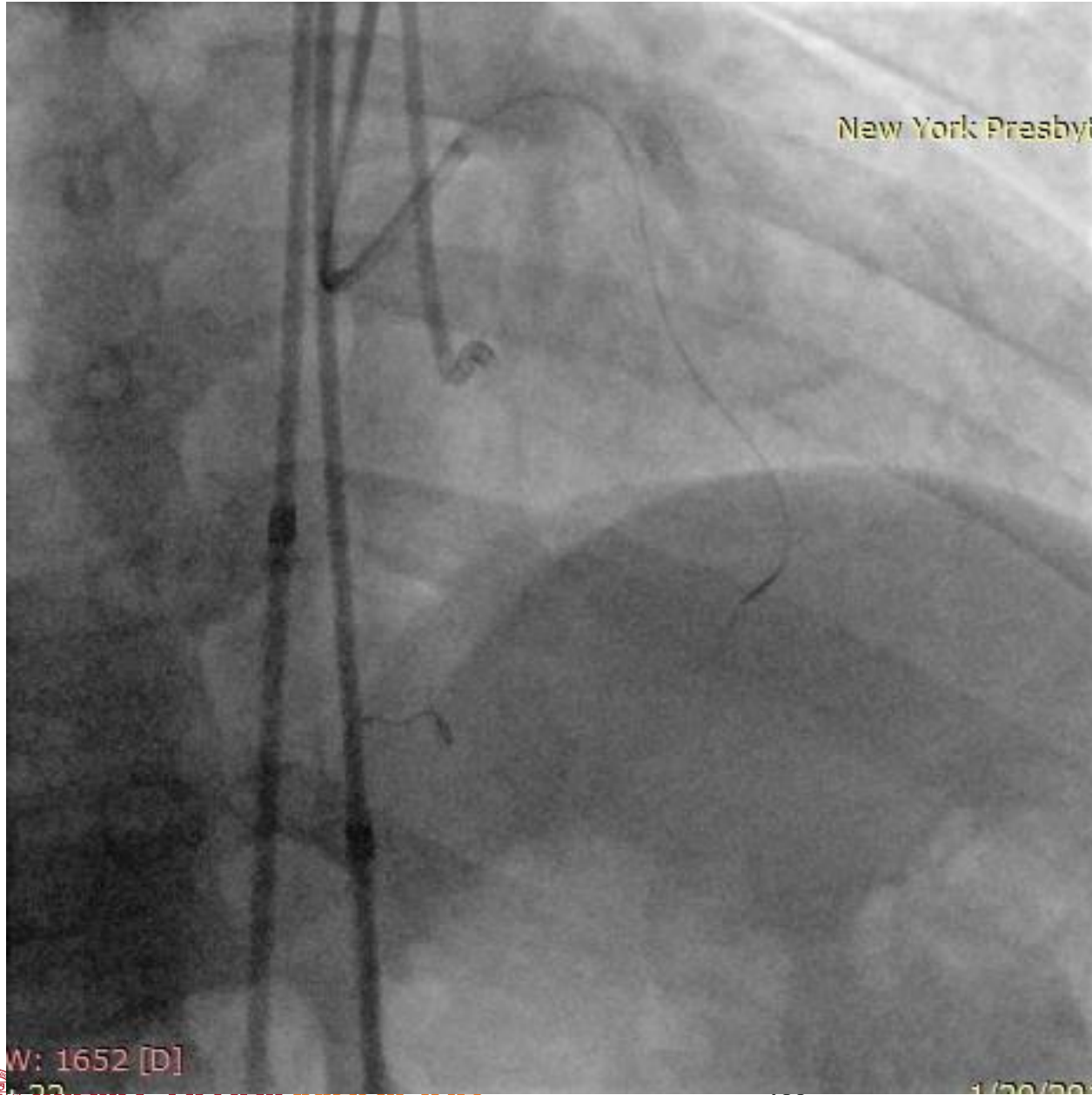
# Retrograde via LAD Septals



TurnPike 150cm

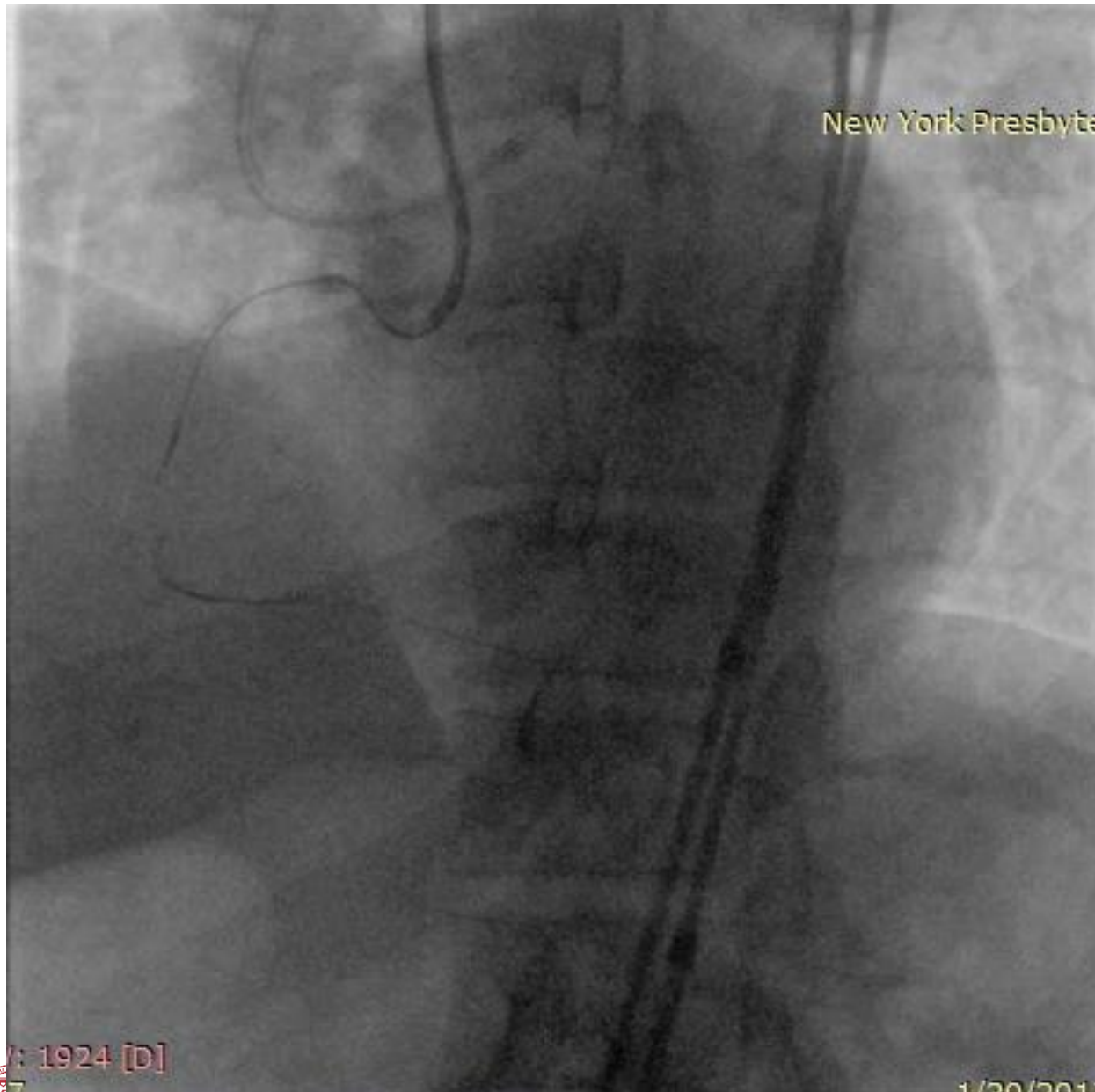


# Retrograde via LAD Septals



**TurnPike 150cm**

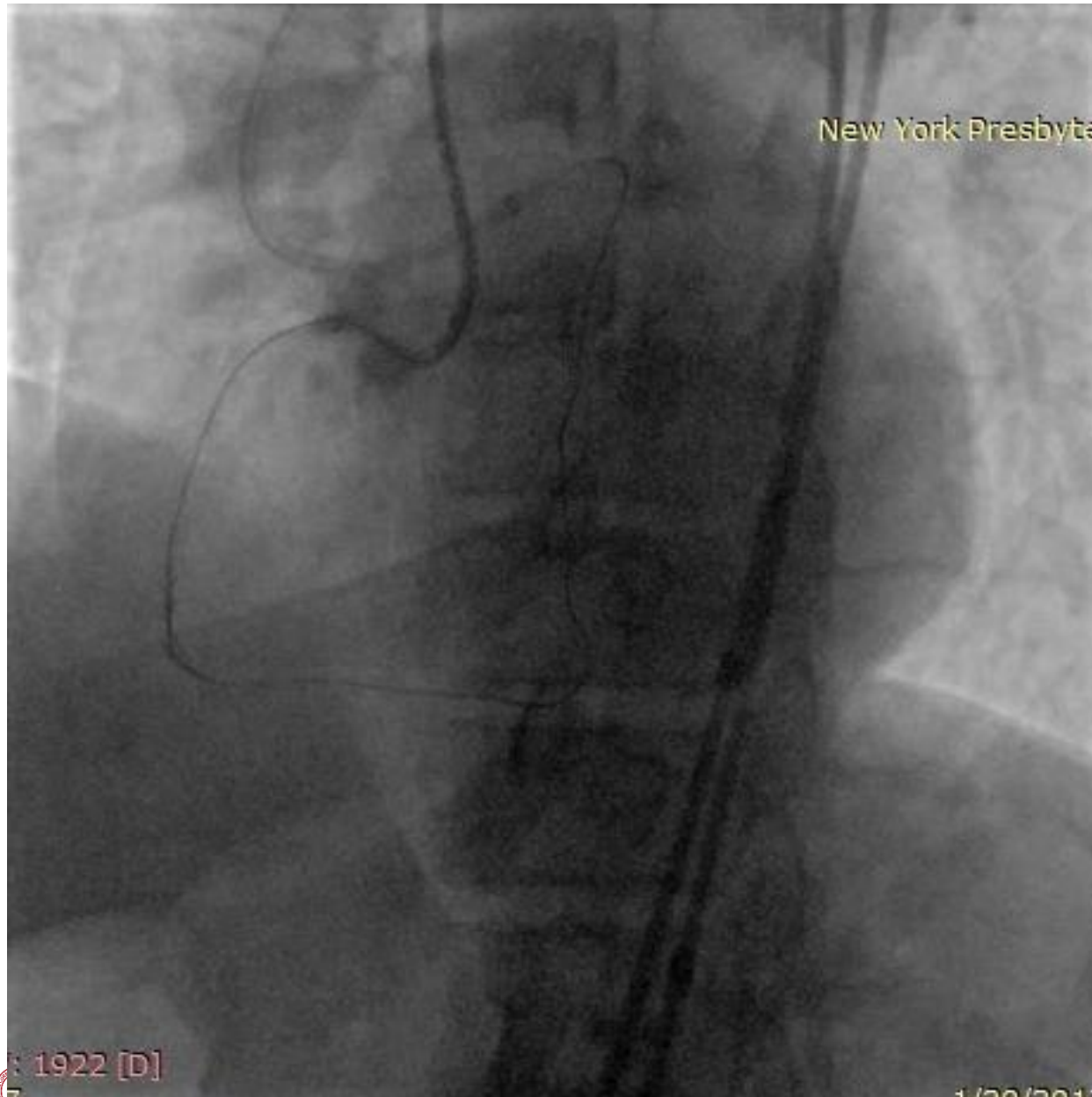
# Setting Up for Reverse CART



TurnPike Spiral 135cm

TurnPike 150cm

# Setting Up for Reverse CART



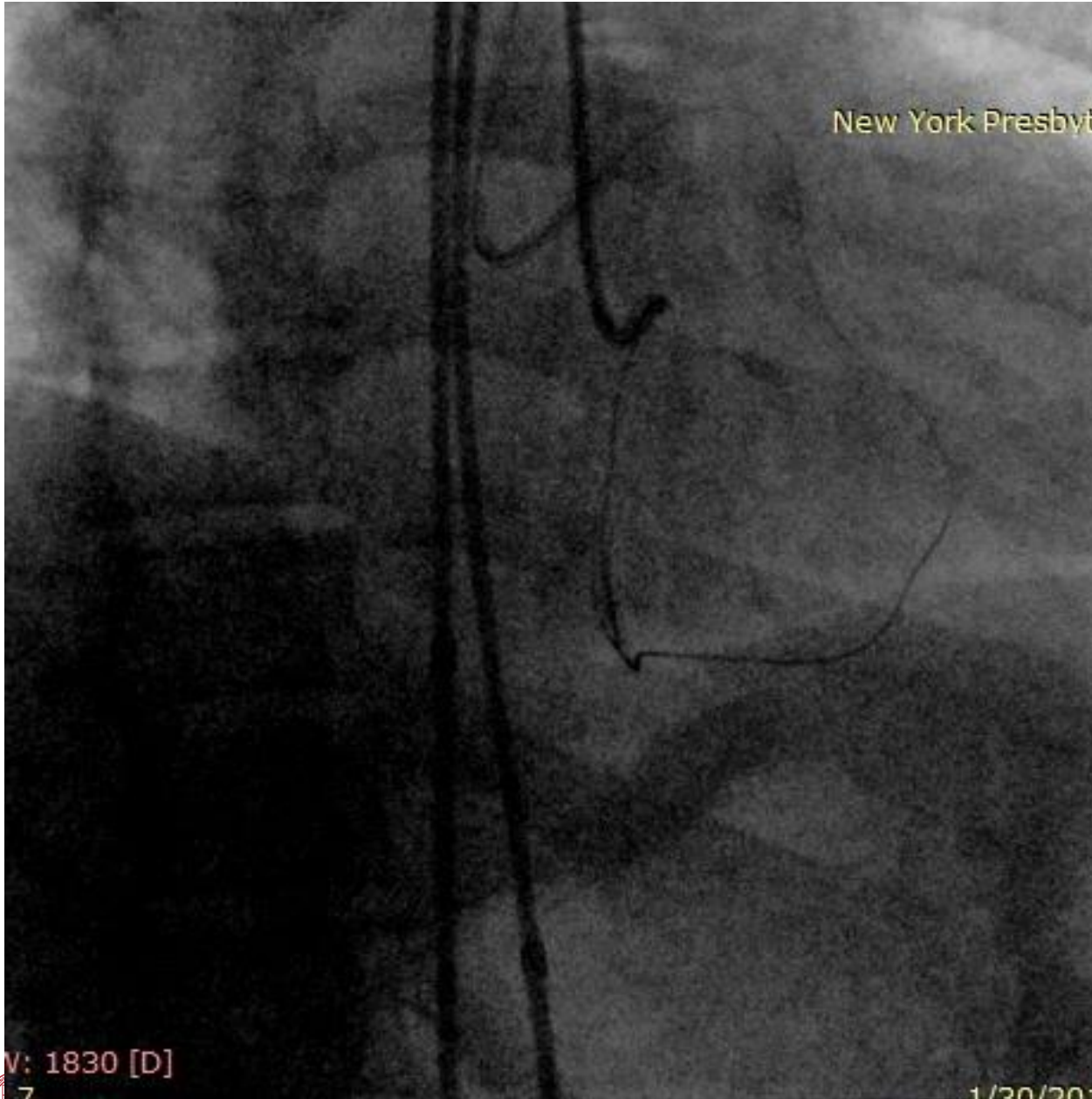
**Antegrade**

**Fielder XT Knuckle**

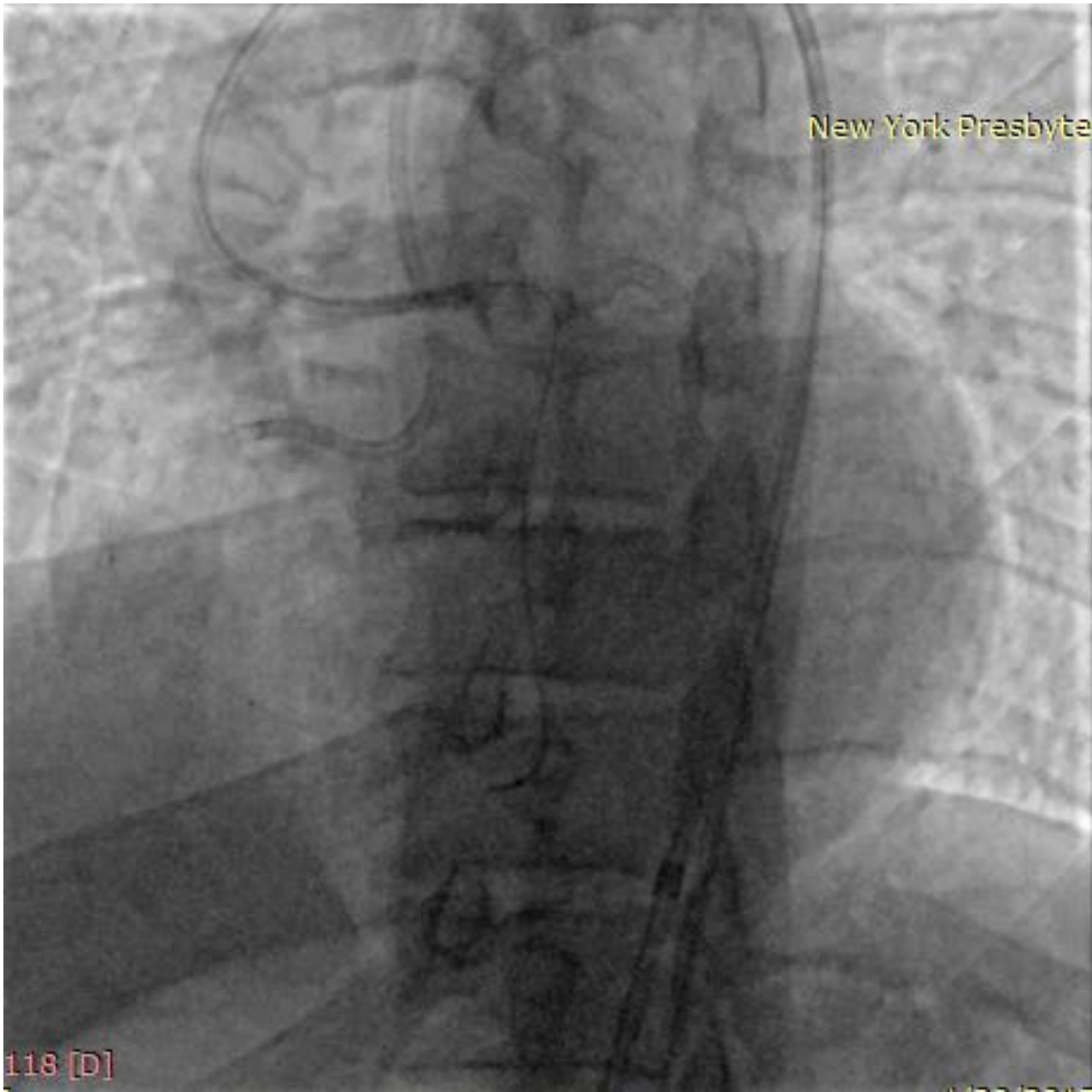**Retrograde**

**Fielder XT Knuckle**

# Setting Up for Reverse CART



“Dancing”

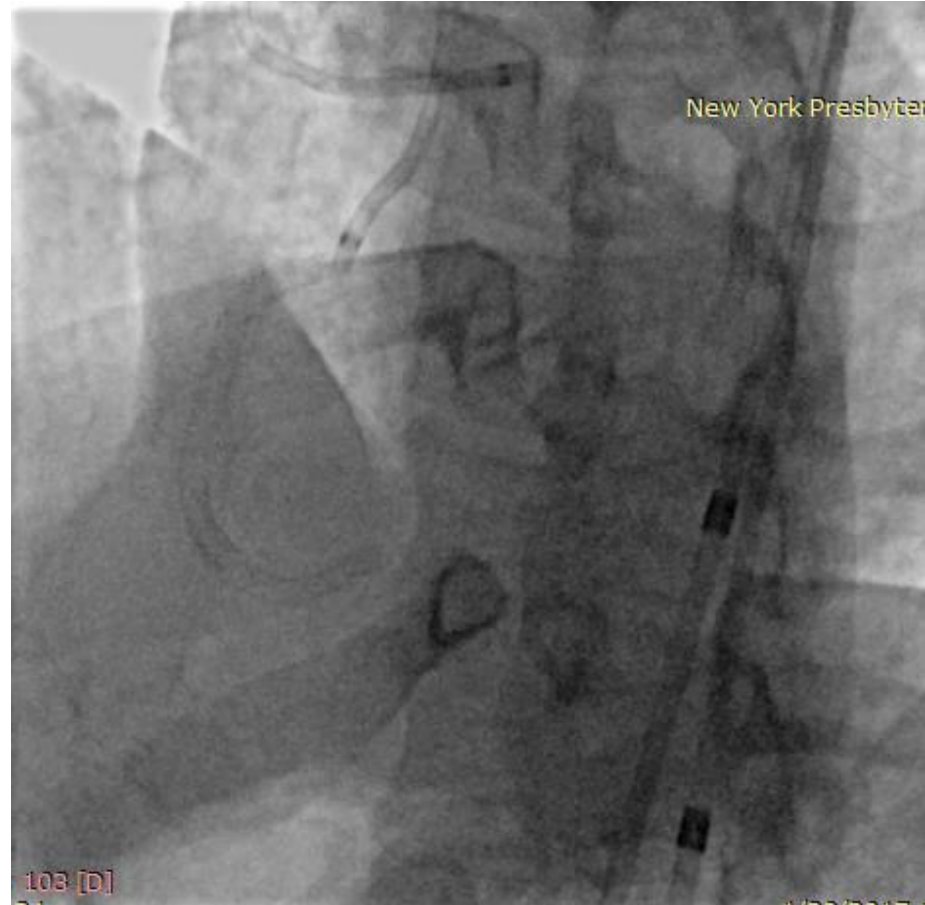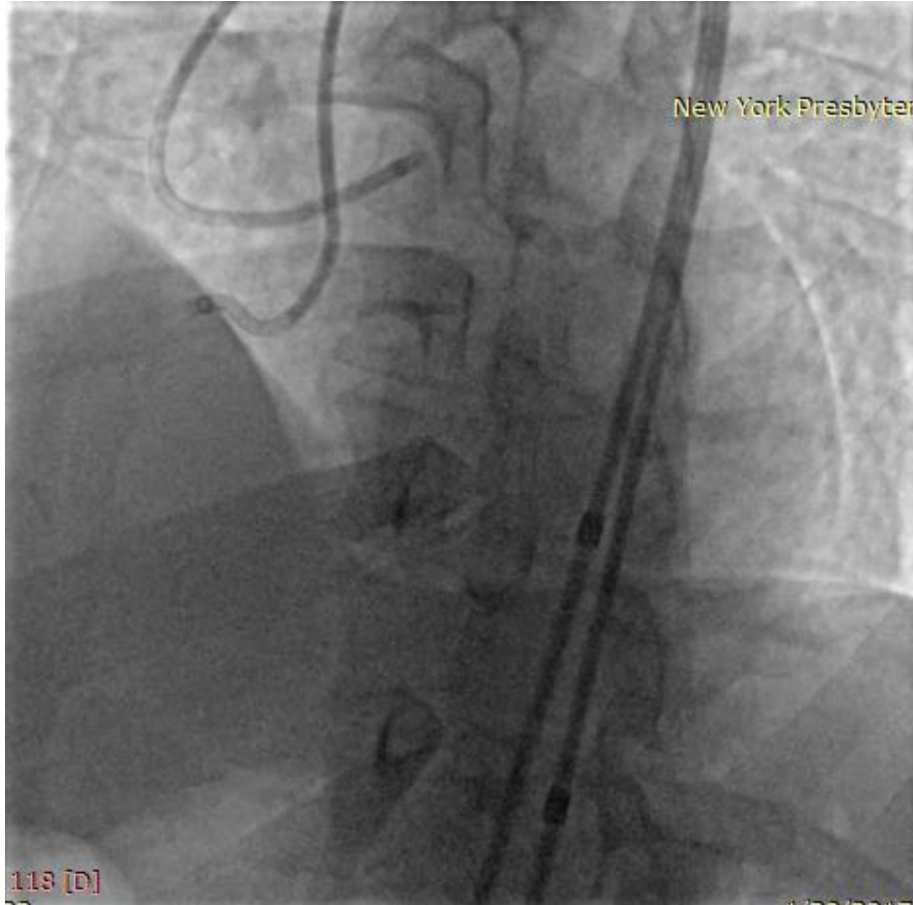


# Gaia 3 Retrograde Crossing

and

# Externalization with RG3 wire

# Final Results after Antegrade IVUS guided PCI over the RG3



Thank You