

# Intravascular Lithotripsy

**Ziad A Ali MD DPhil**

St Francis Hospital & Heart Center  
Cardiovascular Research Foundation, New York, USA

**[zali@crf.org](mailto:zali@crf.org)**

 **Follow me @ziadalinc**

# Disclosure Statement of Financial Interest

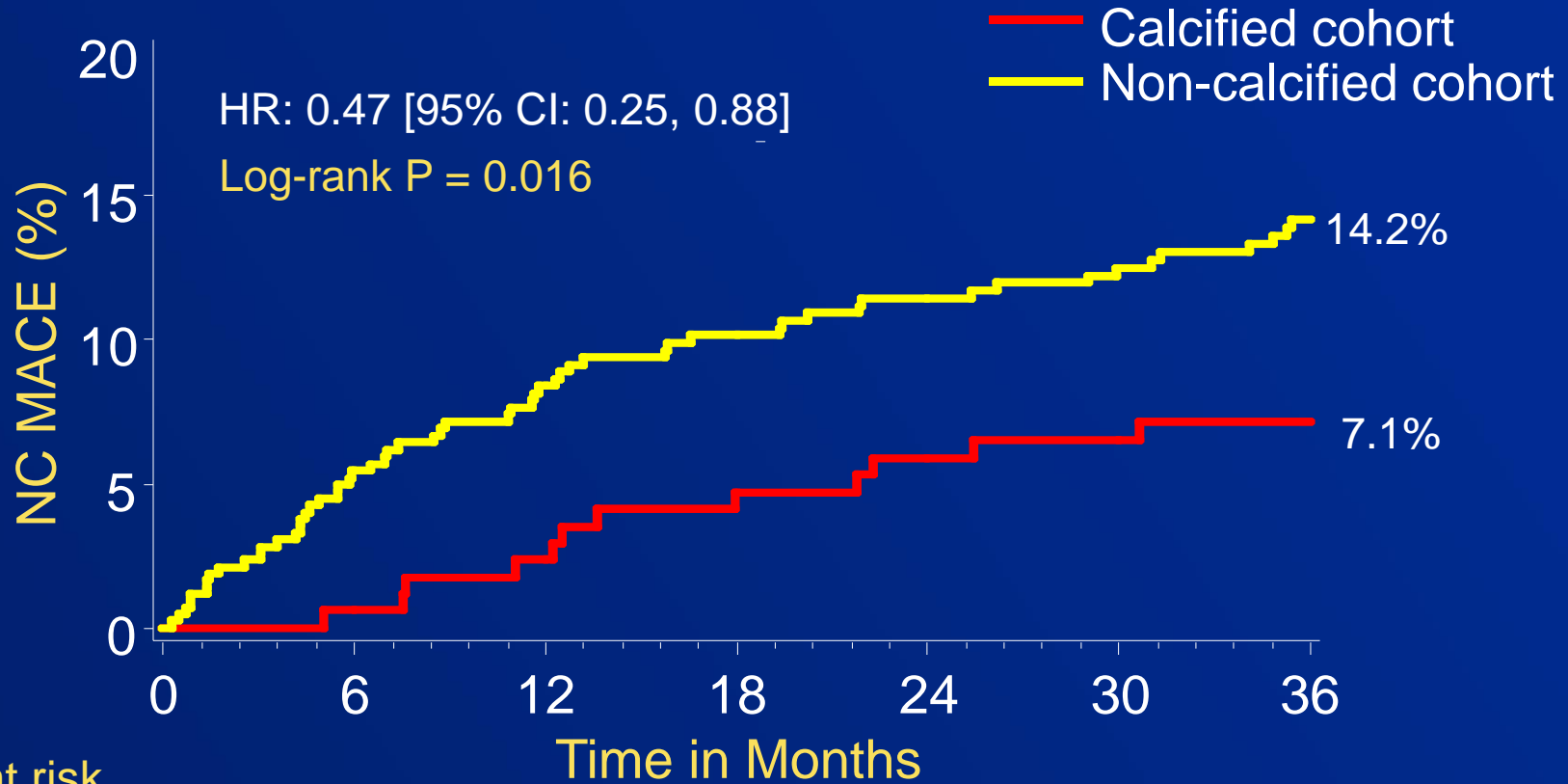
Within the past 12 months, I or my spouse/partner have had a financial interest/arrangement or affiliation with the organization(s) listed below.

Affiliation/Financial Relationship	Company
Grant/Research Support ( <i>Institutional</i> )	NIH/NHLBI, Abbott, Philips, Boston Scientific, Abiomed, Opsens, Acist Medical, Medtronic Cardiovascular Systems Inc
Consulting Fees/Honoraria	Amgen, Astra Zeneca, Boston Scientific
Equity	Shockwave Medical

# *Pre-PCI*

# Plaque composition on outcome

Clinical Outcome of patients with Non-Culprit Calcified Lesions (A PROSPECT Sub-study)



Number at risk

Ca cohort	185	170	166	162	156	150	90
Non-Ca cohort	438	389	370	352	338	324	190

# *Post-PCI*

# Moderate-Severe Calcification: Impact on Ischemic Outcomes

Impact of Calcification on Outcome: Meta-analysis of 11,651 patients from 14 RCT

	Hazard Ratio [95% CI]	P Value
All-cause death	1.46 [1.01, 2.12]	0.043
Ischemic TLR	1.42 [1.13, 1.80]	0.003
ARC definite stent thrombosis	1.83 [1.07, 3.14]	0.027
MACE (Death/MI/TLR)	1.35 [1.14, 1.60]	0.0004

Covariates included in the model:

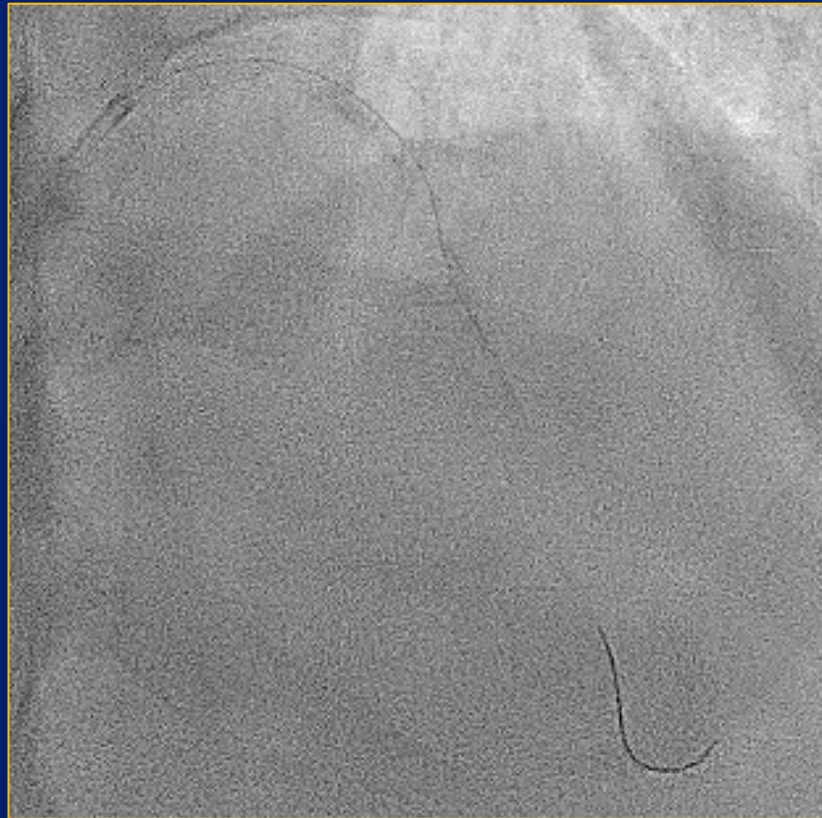**Death:** Moderate/severe calcification, age, gender, diabetes: any, diabetes: insulin, current smoker, prev CABG, prev MI, prior PCI, unstable angina, number stents implanted, LAD lesion treated, baseline RVD, baseline MLD, baseline TIMI 0/1

**Ischemic TLR and MACE:** Moderate/severe calcification, age, gender, diabetes: any, diabetes: insulin, current smoker, hypertension, hyperlipidemia, prev CABG, prev MI, prior PCI, unstable angina, number stents implanted, LAD lesion treated, ostial location, lesion length, baseline RVD, baseline MLD, baseline TIMI 0/1

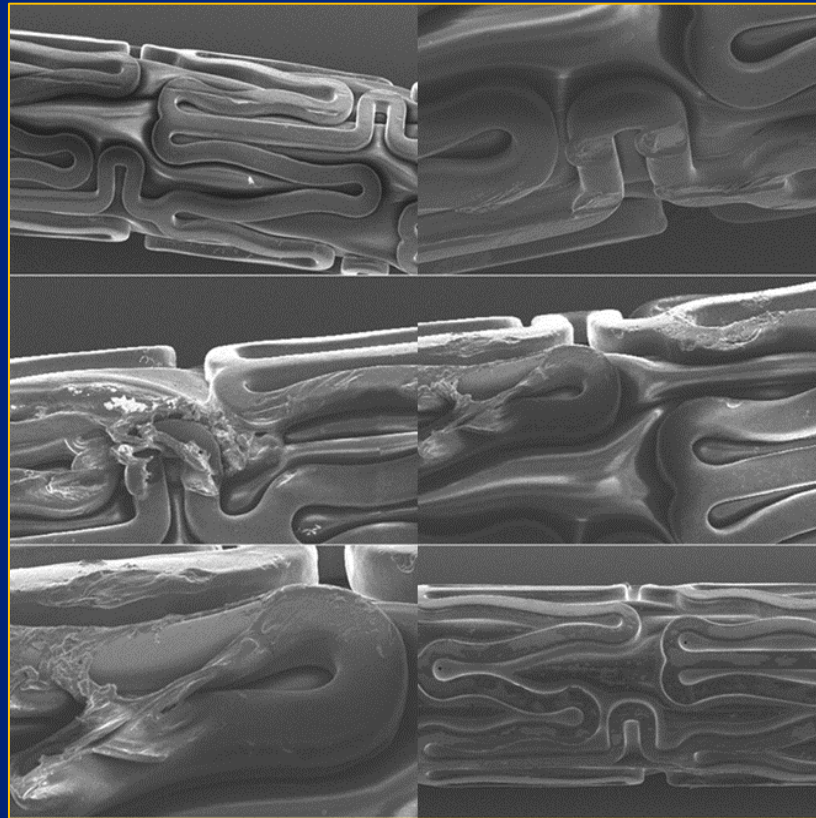
**ARC definite ST:** moderate/severe calcification, age, diabetes: any, current smoker, prev MI, unstable angina, baseline RVD, baseline TIMI 0/1

# Impact of Coronary Calcification

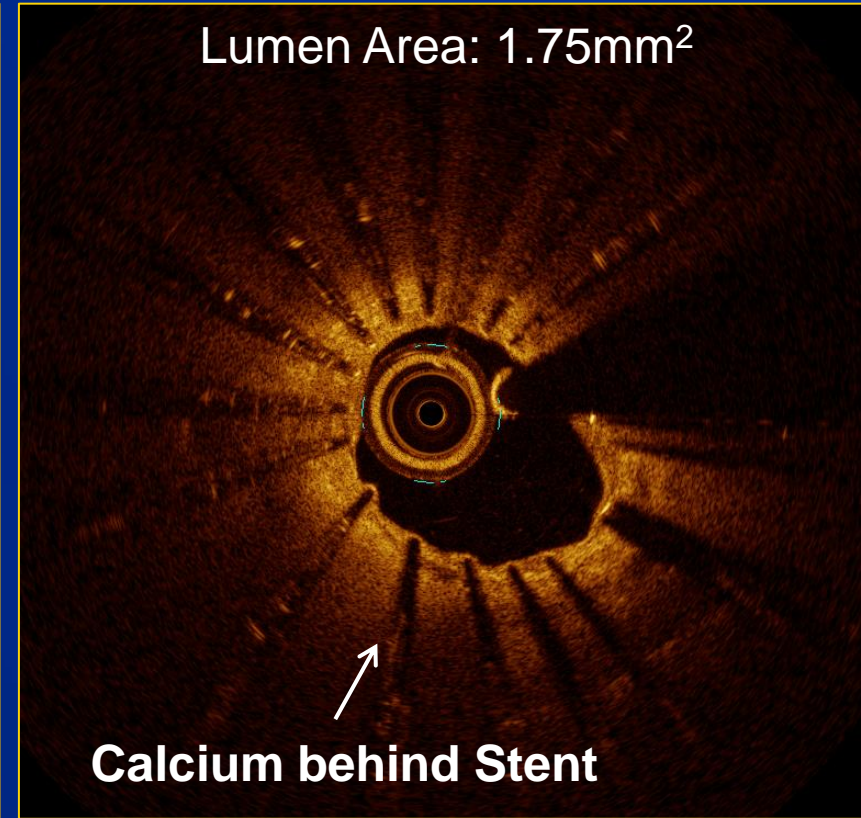
Impairs Device Crossing



Delamination



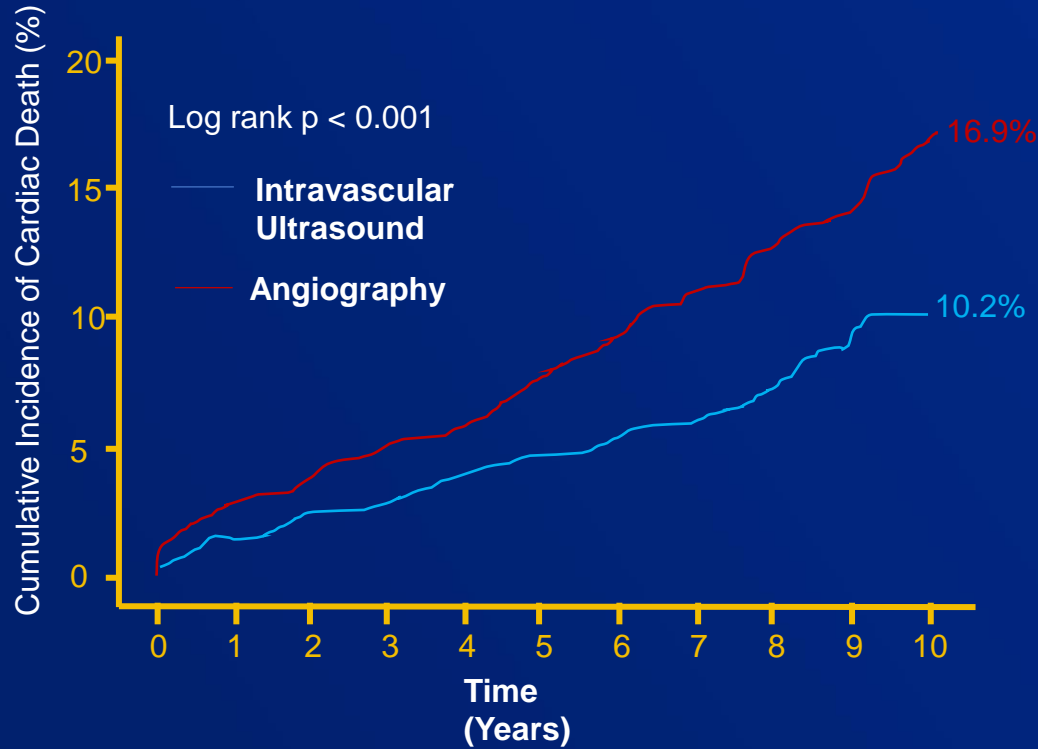
Underexpansion



$\Delta$  elution kinetics

# Outcomes in Complex PCI

## Clinical Outcomes



All Lesion	0.573 (0.460-0.714)
Bifurcation Lesion	0.682 (0.498-0.934)
Chronic Total Occlusion Lesion	0.670 (0.408-1.102)
Left Main Disease	0.203 (0.126-0.329)
Long Lesion	0.602 (0.450-0.804)
Multi-Vessel PCI	0.639 (0.473-0.864)
Multiple Stents Implantation	0.532 (0.332-0.855)
In-Stent Restenosis Lesion	0.837 (0.403-1.740)
Calcified Lesion	0.458 (0.052-4.012)

0.01 0.1 1 10  
Favors Intravascular Ultrasound

Favors Angiography

JACC Interv. 2019 Apr 8;12(7):607-620

# Risk Factors for Target Vessel Failure

High Risk Clinical and Lesion Characteristics  
Pooled analysis of 13,380 pts from contemporary DES trials  
(cardiac death, TV-MI, or ID-TVR)

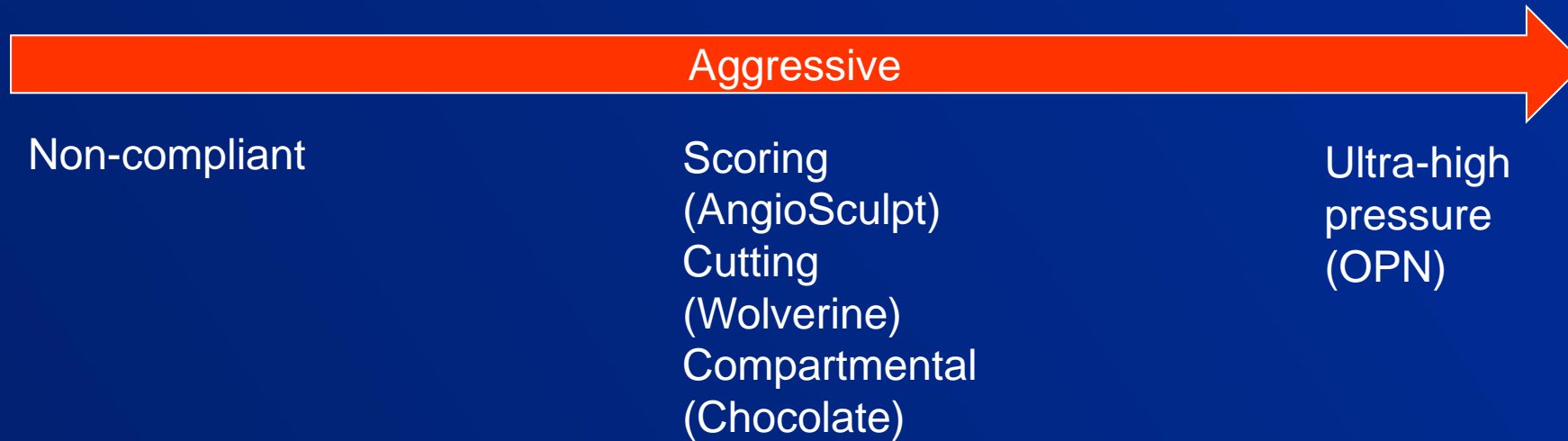	<b>RR [95% CI]</b>	<b>P</b>
Diabetes*	1.50 [1.28, 1.76]	<0.0001
ACS NSTEMI*	1.42 [1.31, 1.54]	<0.0001
Stent Length >28mm*	1.14 [1.06, 1.23]	<0.001
Bifurcation <sup>#</sup>	1.31 [1.11, 1.56]	0.0019
Moderate to Severe Ca <sup>2+</sup> *	1.62 [1.37, 1.91]	0.06
Chronic Total Occlusion <sup>#</sup>	1.31 [0.99, 1.75]	<0.0001
In-Stent Restenosis <sup>#</sup>	1.88 [1.57, 2.26]	<0.0001
CKD/ESRD <sup>#</sup>	1.82 [1.55, 2.13]	<0.0001

# Goals of therapy in CAC

## Cross the lesion/Modify Plaque

- **Cross the lesion**
  - enables lesion access for upscaling balloons and stents.
- **Plaque modification:**
  - Debulking calcific plaque
  - Inducing calcium fracture
  - Maximizing luminal gain (stent expansion)

# Balloon Based Strategy



Device	ACCF/AHA/SCAI 2011	ESC/EAPCI 2014
<b>Cutting balloon angioplasty</b>	<ul style="list-style-type: none"> <li>• Might be considered to avoid slippage induced coronary artery trauma during PCI for in-stent restenosis or ostial lesions in side branches. (<b>Class IIIb-C</b>)</li> <li>• Should not be performed routinely during PCI. (<b>Class III-A</b>)</li> </ul>	May be useful in highly calcified, rigid ostial lesions.

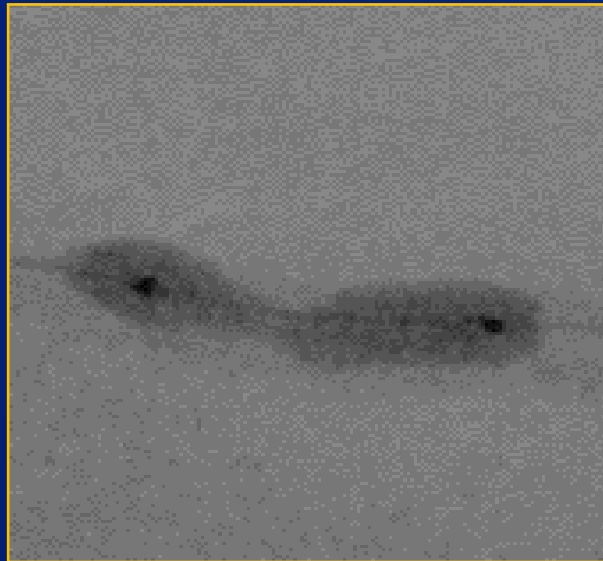
# Non-Balloon Based Strategies

- Lazer Atherectomy
- Rotational Atherectomy
- Orbital Atherectomy

Device	ACCF/AHA/SCAI 2011	ESC/EAPCI 2014
Rotational atherectomy	<ul style="list-style-type: none"><li>• Reasonable for fibrotic or <i>heavily calcified lesions</i> that might not be crossed by a balloon catheter or adequately dilated before stent implantation. (<b>Class IIa-C</b>)</li><li>• Should not be performed routinely for de novo lesions or in-stent restenosis. (<b>Class III-A</b>)</li></ul>	Might technically be required in cases of tight and calcified lesions, to allow subsequent passage of balloons and stents.

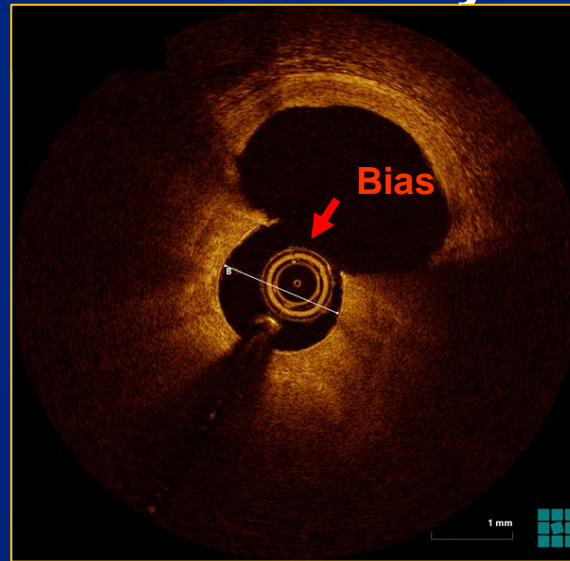
# Limitations of Existing Technologies

## Balloon Based



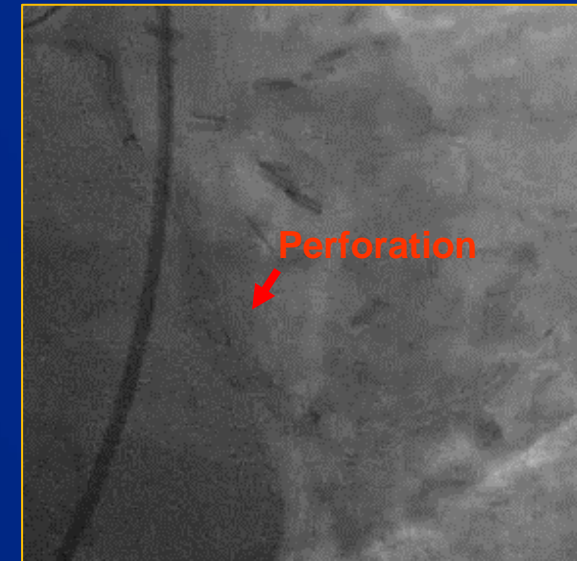
### Insufficient Force

## Atherectomy



### Wire Bias

## Lazer

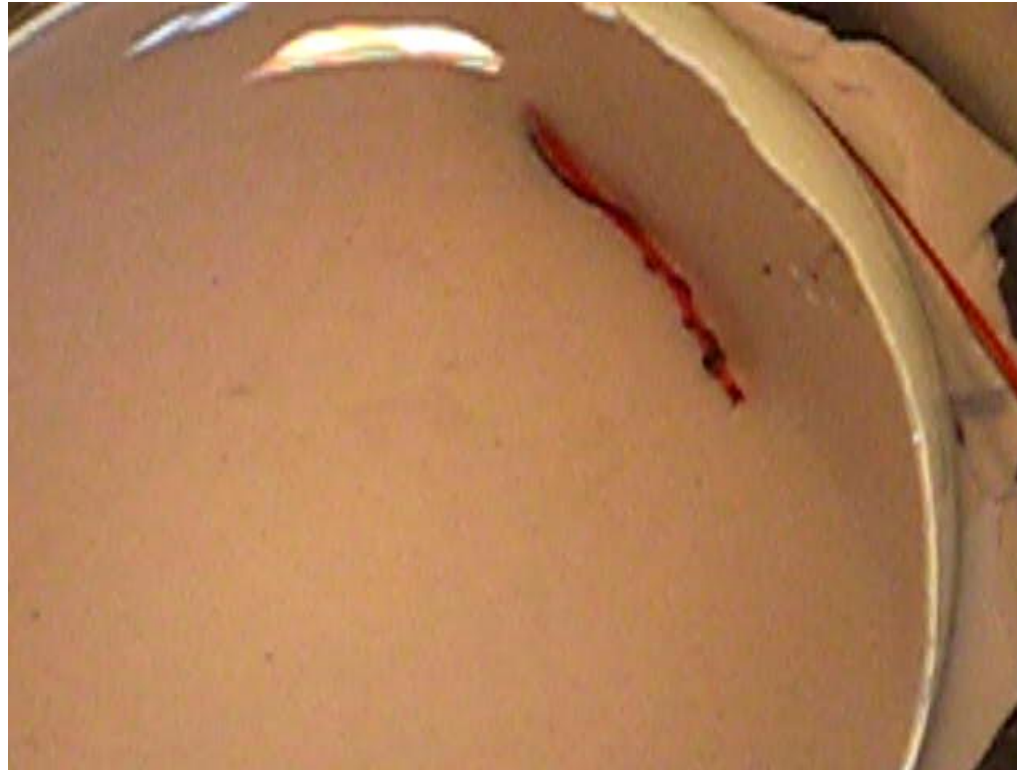


### Unpredictable

*IVL*

# Intravascular Lithotripsy – Where it all began

- Fall of 2009
- Sunday evening in a hourly rental lab, somewhere in Mountain View, Ca
- A MacGyver'd lithotripsy device
- Eggs from a Safeway in Mountain View (or John Adams ranch)
- iPhone 1



“it’s doing something”

“looks like it blew a whole in the back side, what we’re seeing on the front side is the membrane”

“I think this is going to work”

# Intravascular Lithotripsy

- Expanding and collapsing vapor bubble creates a short burst of acoustic pressure waves
- Acoustic pressure waves travel through the vessel tissue with an effective pressure of ~50 atm
- A localized field effect within the vessel fractures both superficial and deep calcium

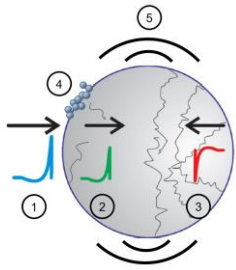


# Mechanism of Action

Balloon



IVL



- Cracks due to compression are parallel to the applied force.
- Tensile cracks are perpendicular to the applied force.
- Shear cracks are perpendicular to the tensile stress.

# Mechanism of Action

IVL




(Ultra) high pressure balloon




# Mechanism of Action

## Calcium Fracture

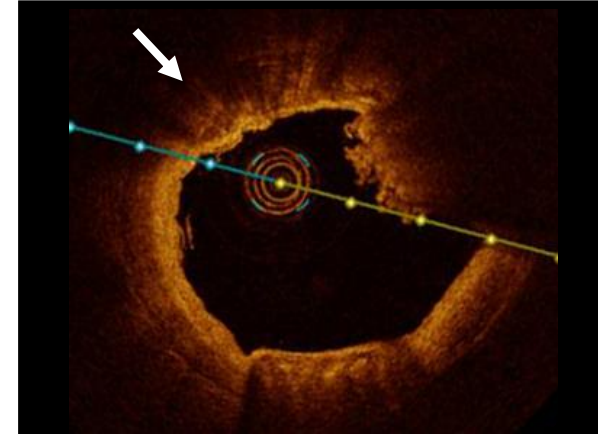
Pre-IVL



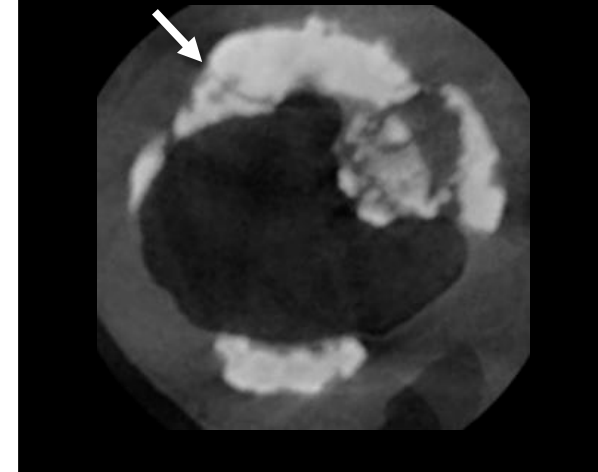
Post-IVL



OCT



Micro-CT




Kereiakes and Ali et al. JACC Interv. 2021 28;14(12):1275-1292

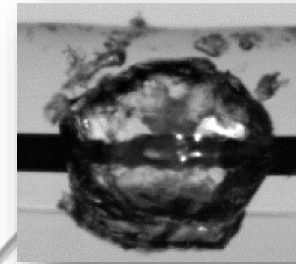
# Intravascular Lithotripsy: MOA I

- High Speed Sonic Pressure Wave Created Inside Integrated Balloon

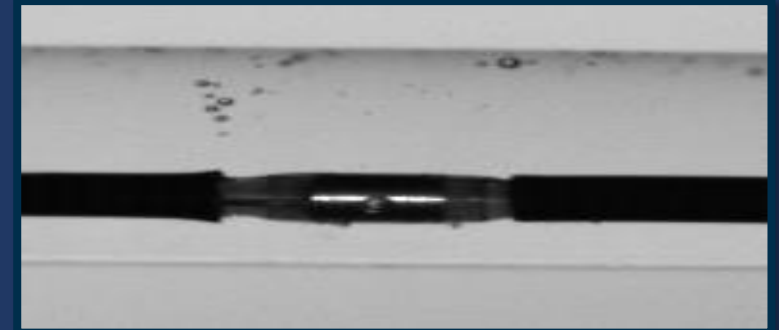
**1** Unfocused lithotripsy energy is created at the emitters which are contained in a fluid filled coupler.



**2** Electrical energy is delivered to the emitter, initiating the steam bubble, which expands & collapses – creating sonic pressure waves.



[Video: Actuation of Single Pulse \(20 \$\mu\$ s/frame\)](#)



# *Algorithm for Calcified Lesions*

# Choices

**IVL – Smash it**



**Break it - Lazer**



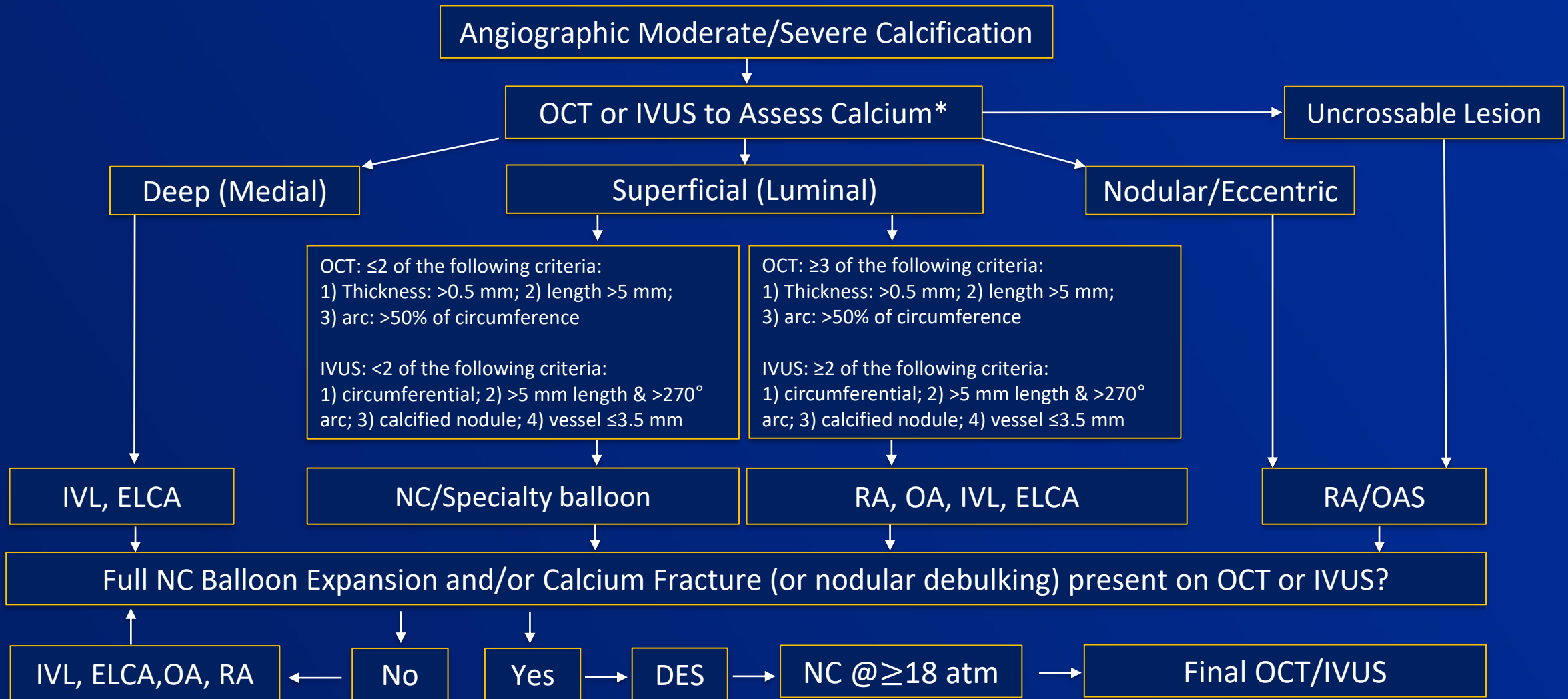
**Grind it - RA, OA**



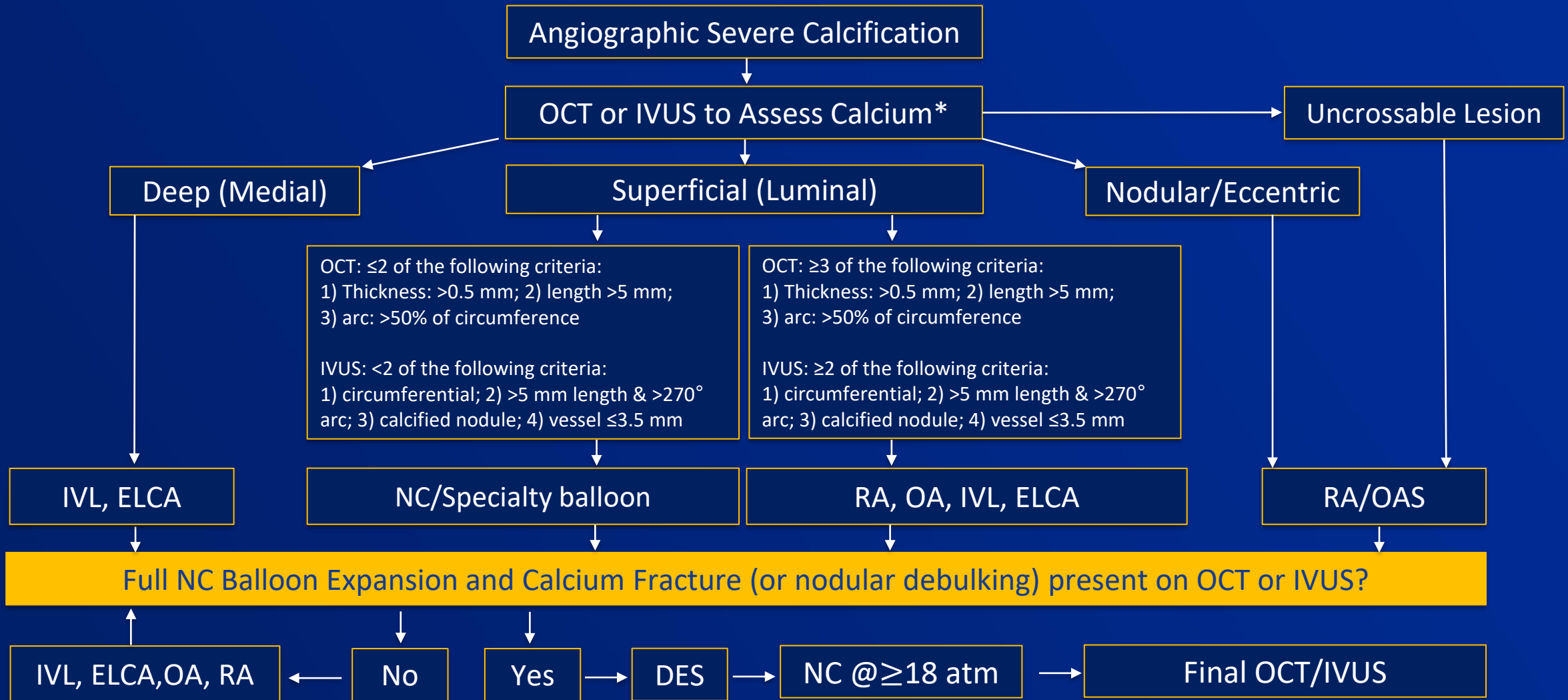
**Tear it- NC Balloon**



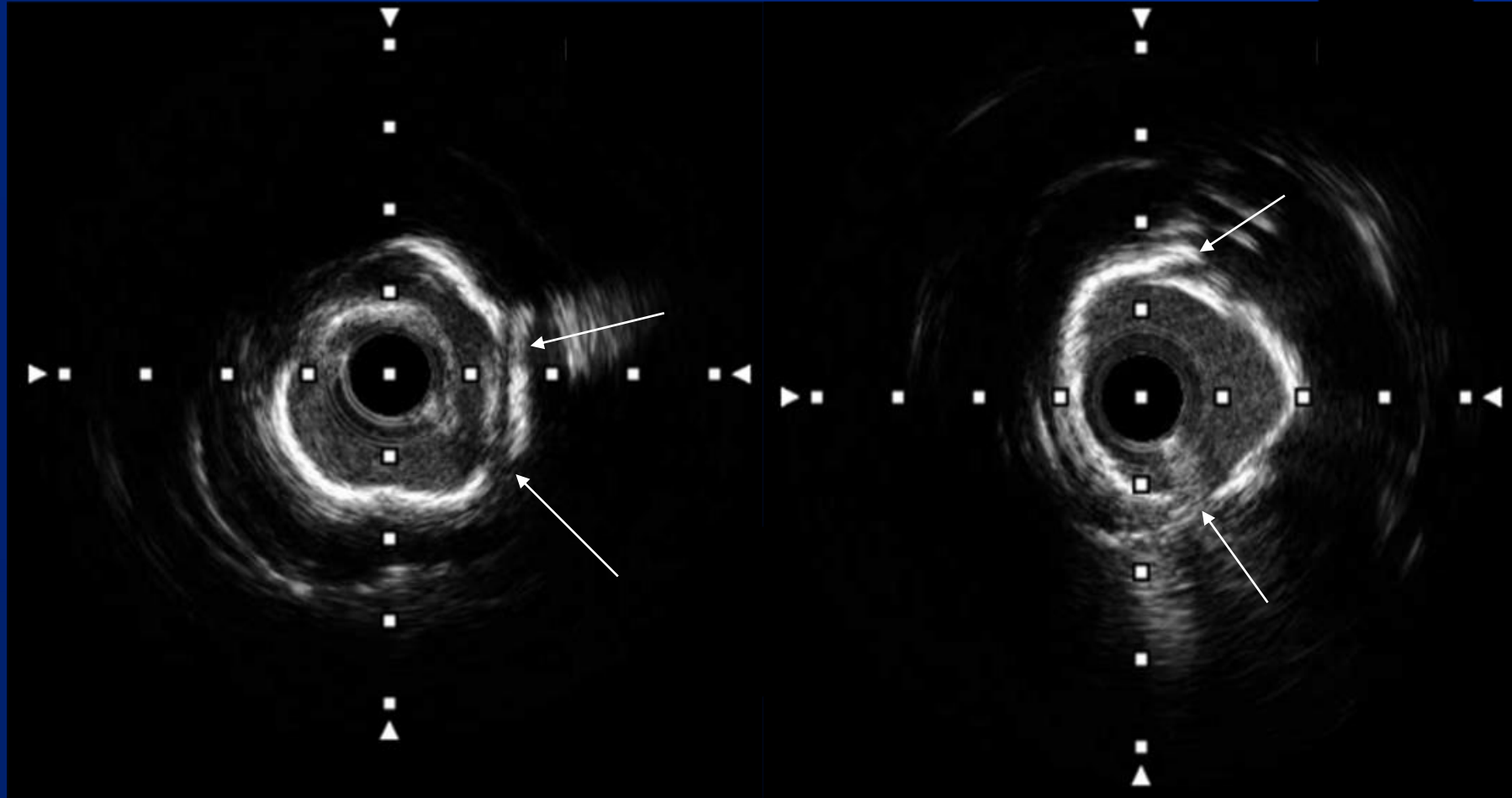
# Algorithmic Approach



# Algorithmic Approach

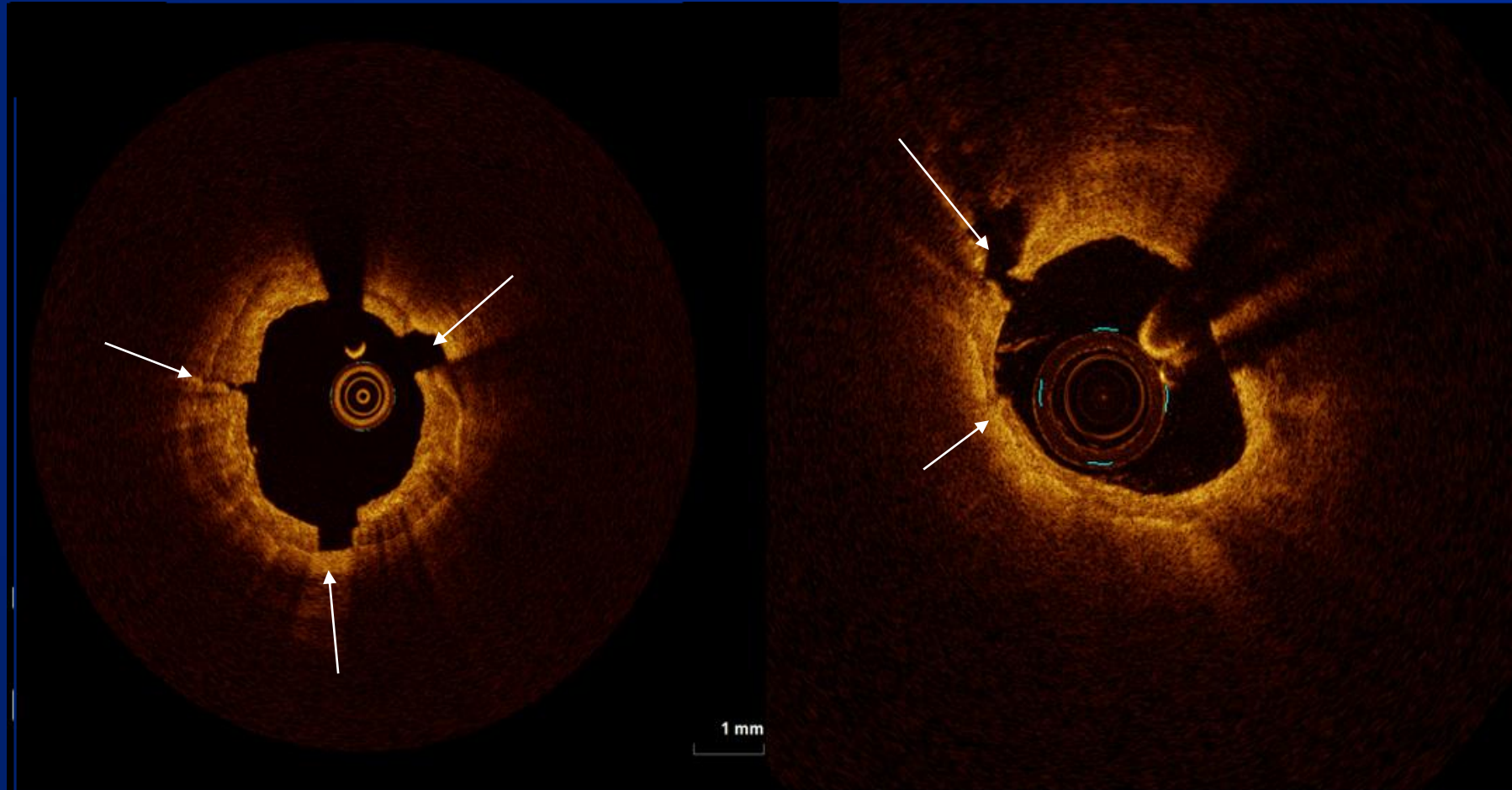


# Calcium Fracture

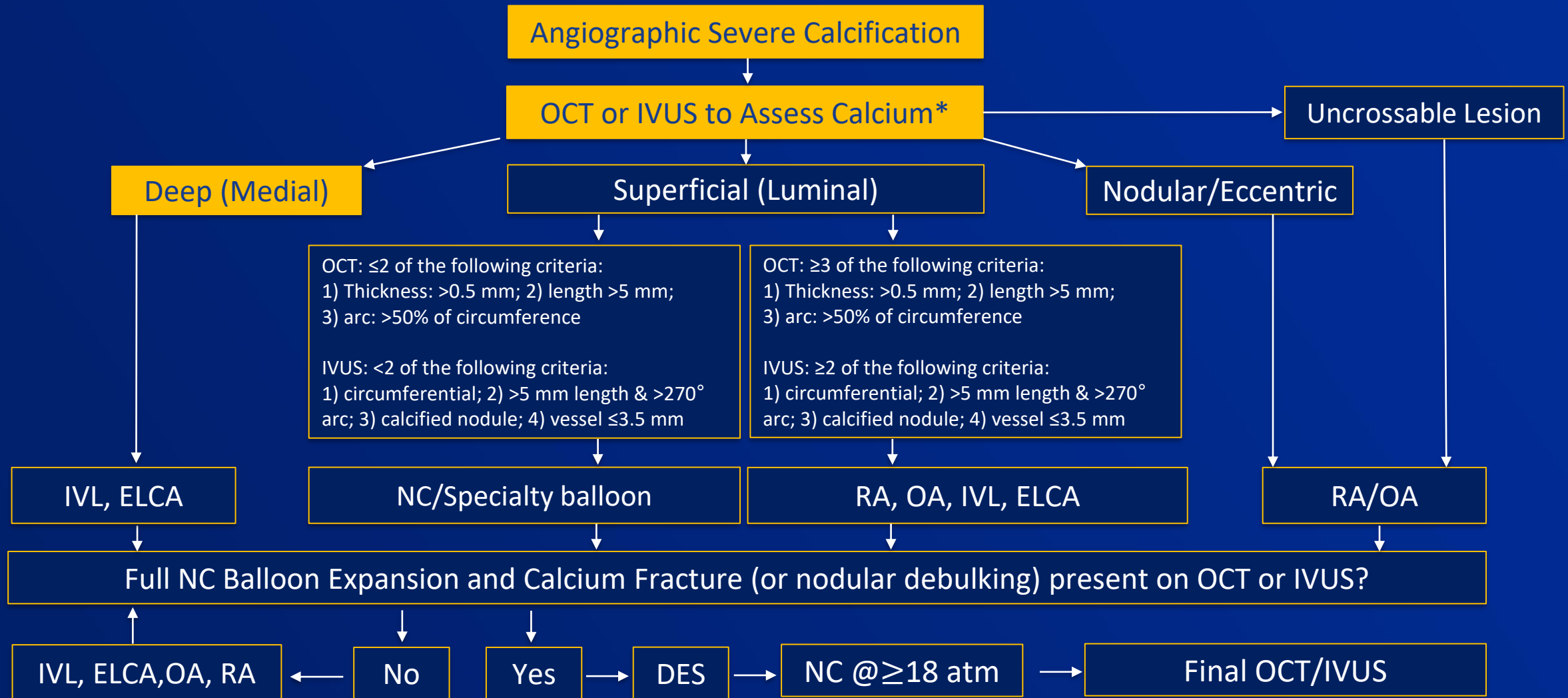


IVUS calcium fracture

# Calcium Fracture

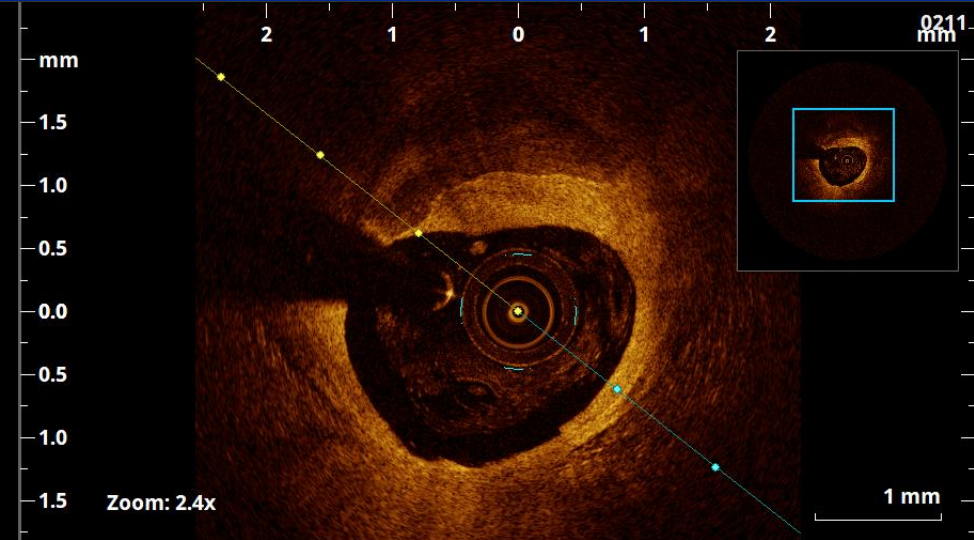
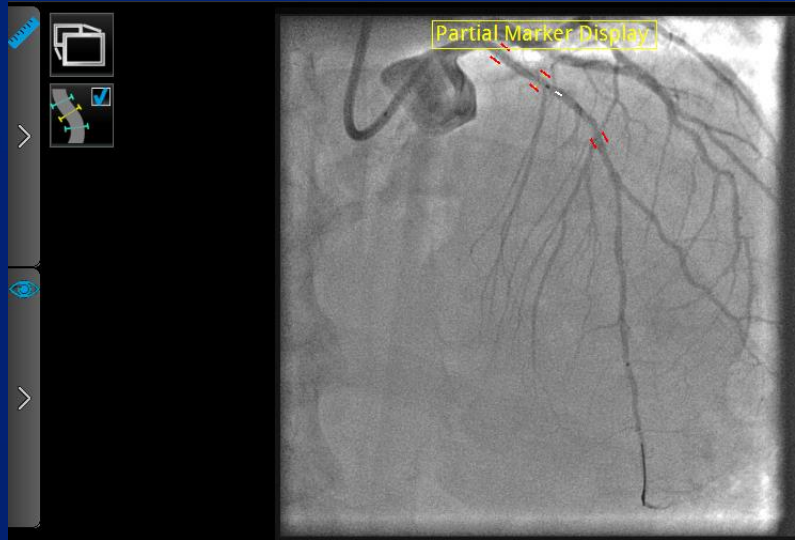


# Algorithmic Approach

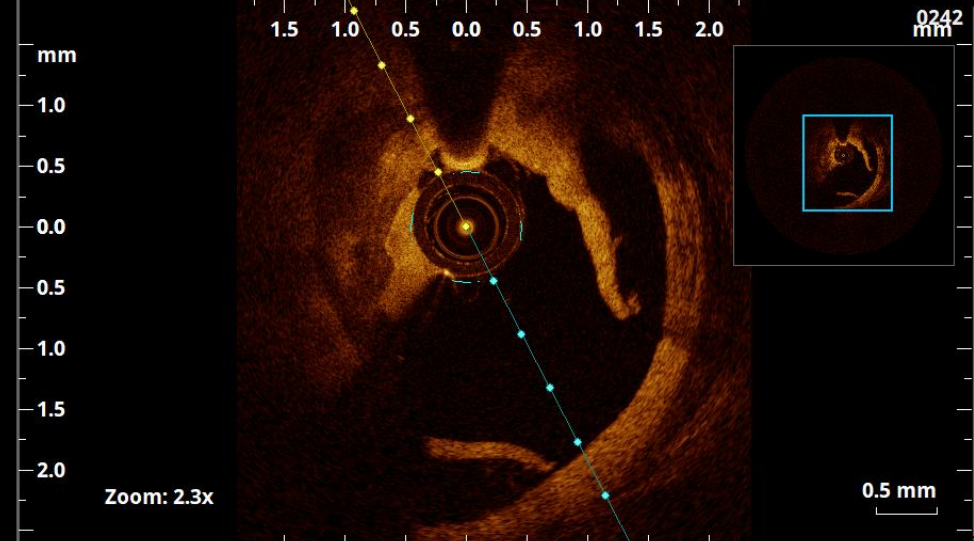
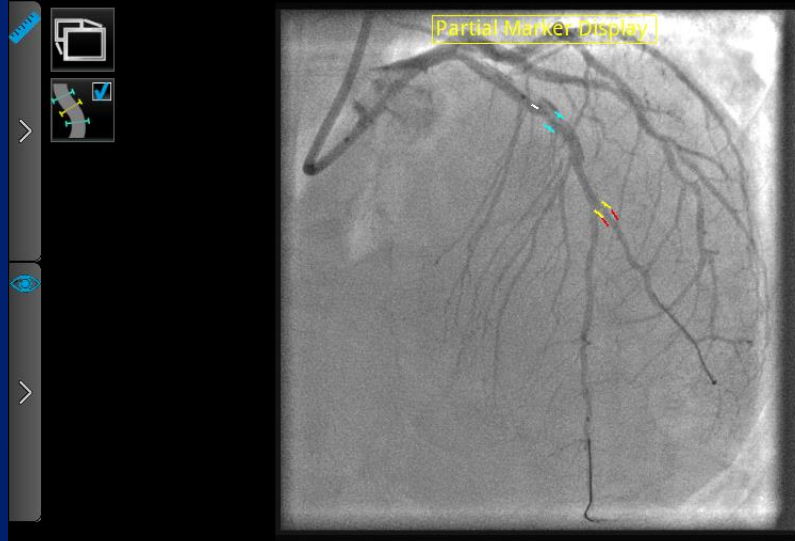


# Deep (Medial) Calcification - Atherectomy

Pre-PCI



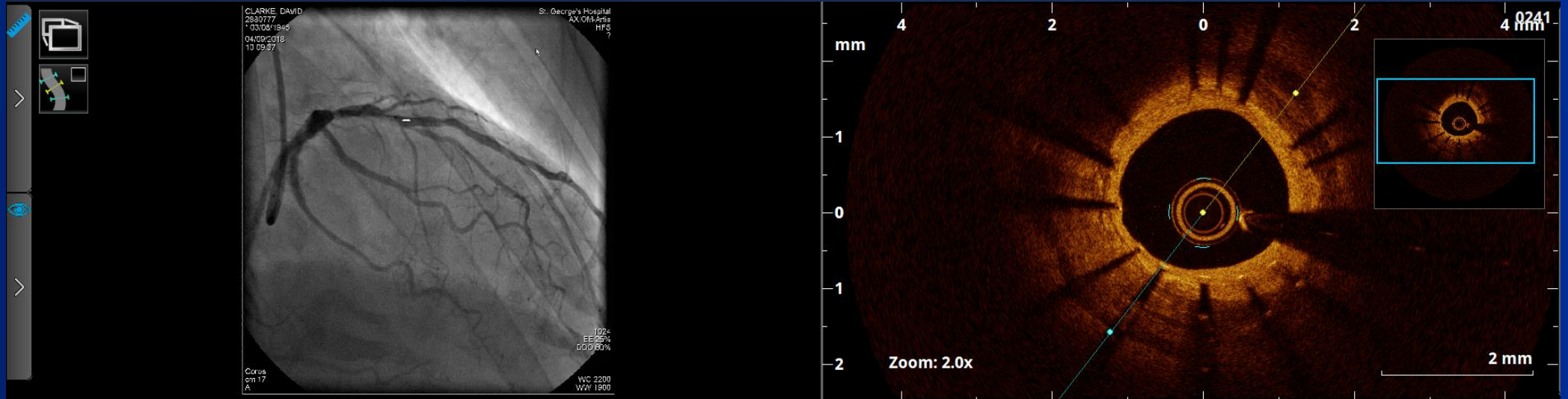
Post-OAS-NC



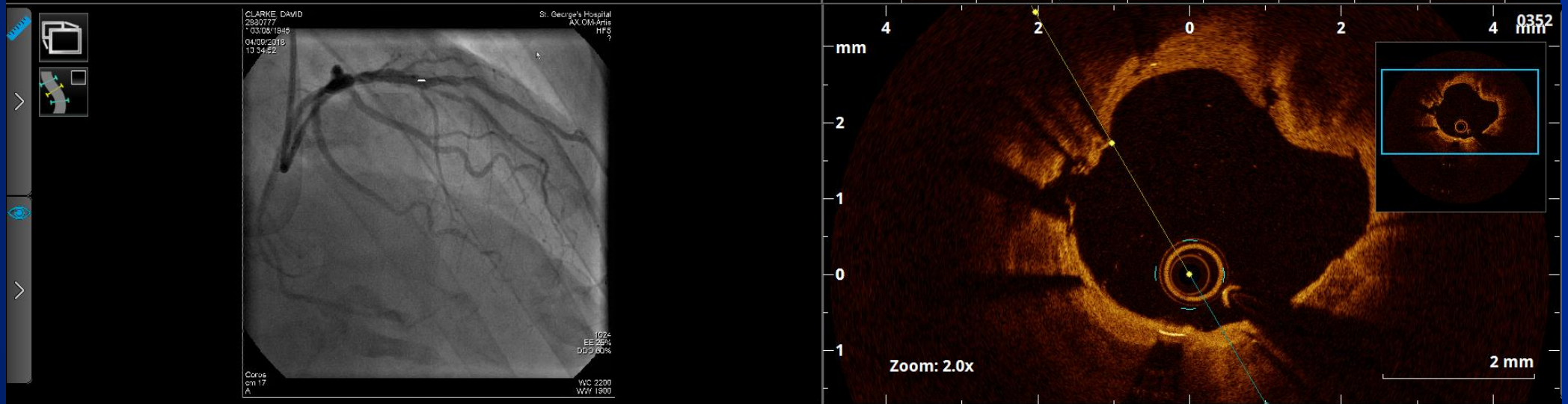
- ~~In Thick-cap Fibrocalcific plaque atherectomy is limited~~

# Deep (Medial) Calcification - IVL

Pre-PCI



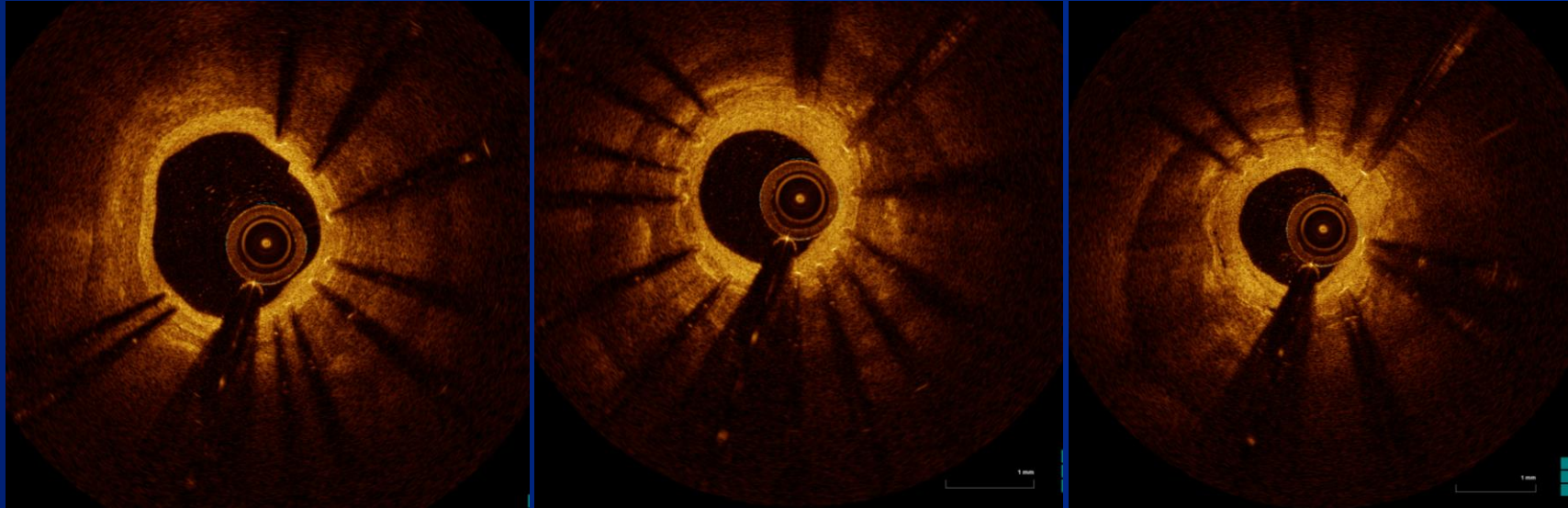
Post-IVL-NC



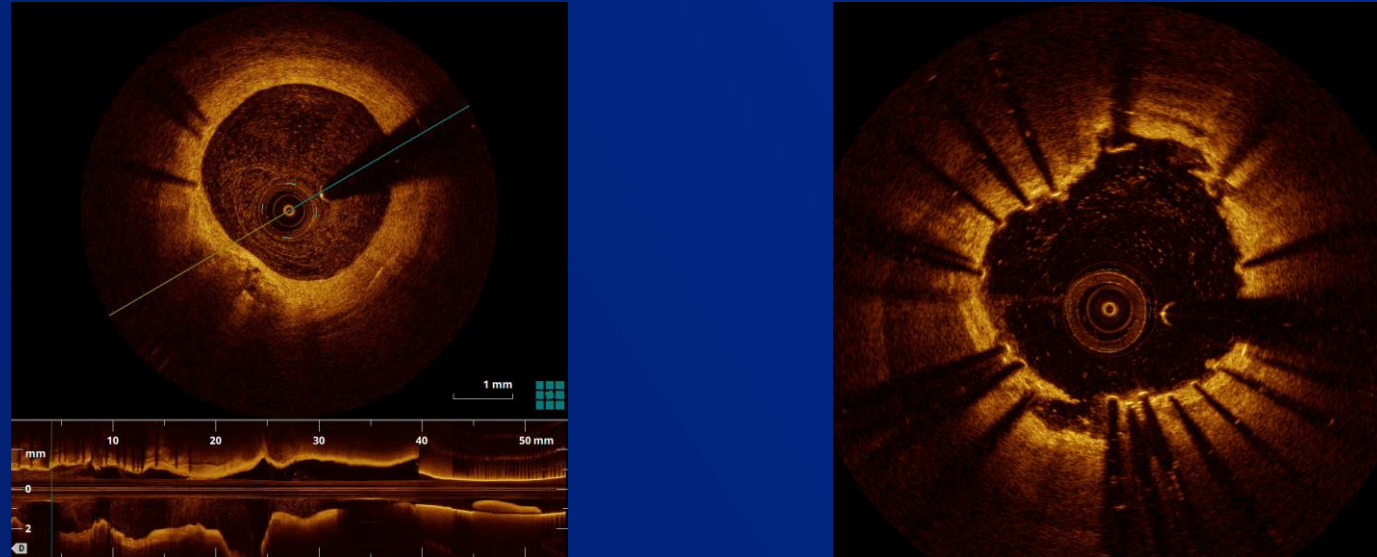
- In Thick-cap Fibrocalcific plaque IVL may induce  $\text{Ca}^{2+}$  fracture

# Deep (Medial) Calcification - ELCA

Pre-PCI

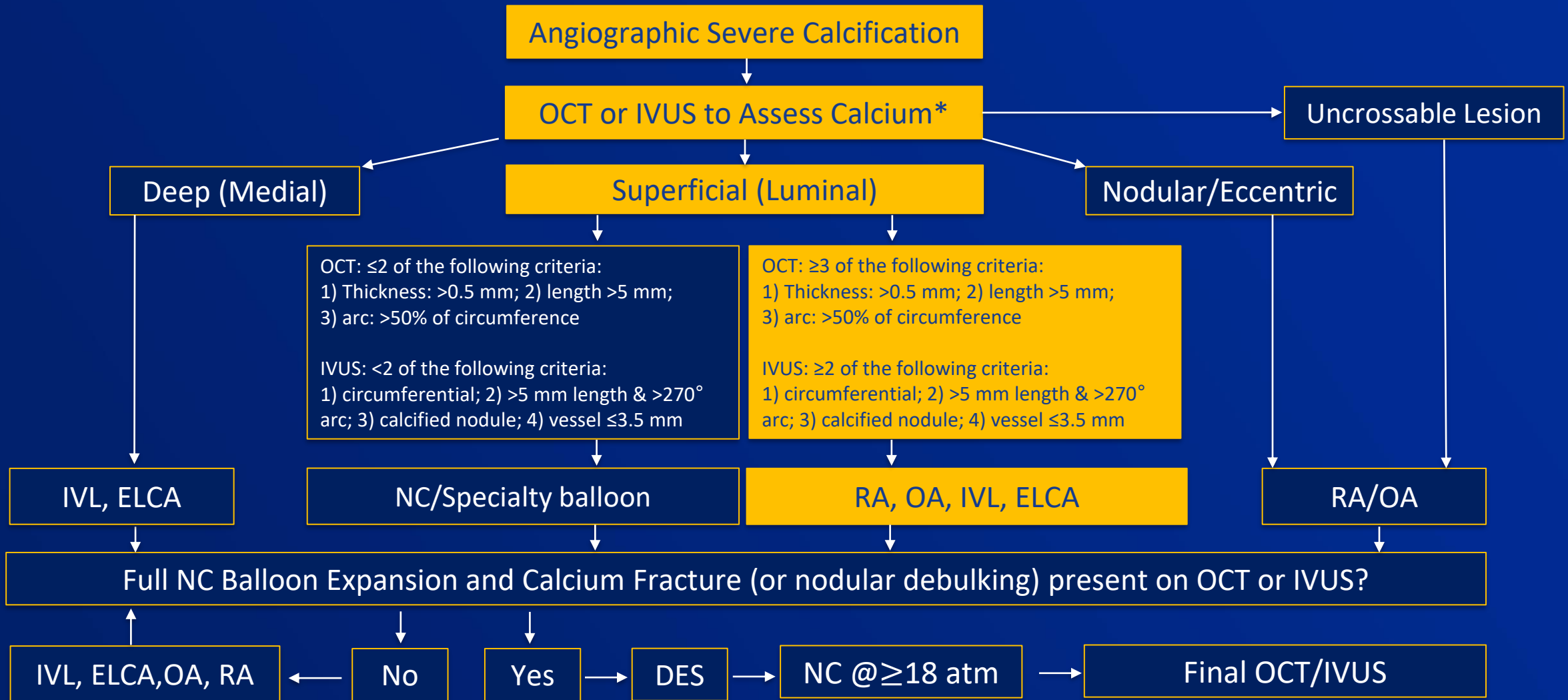


Post-ELCA-NC

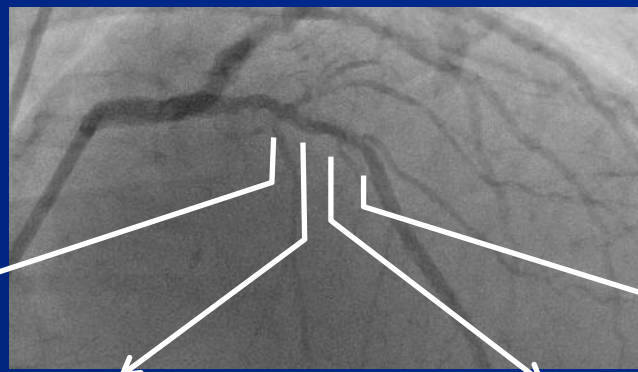


- In Thick-cap Fibrocalcific plaque IVL may induce fracture

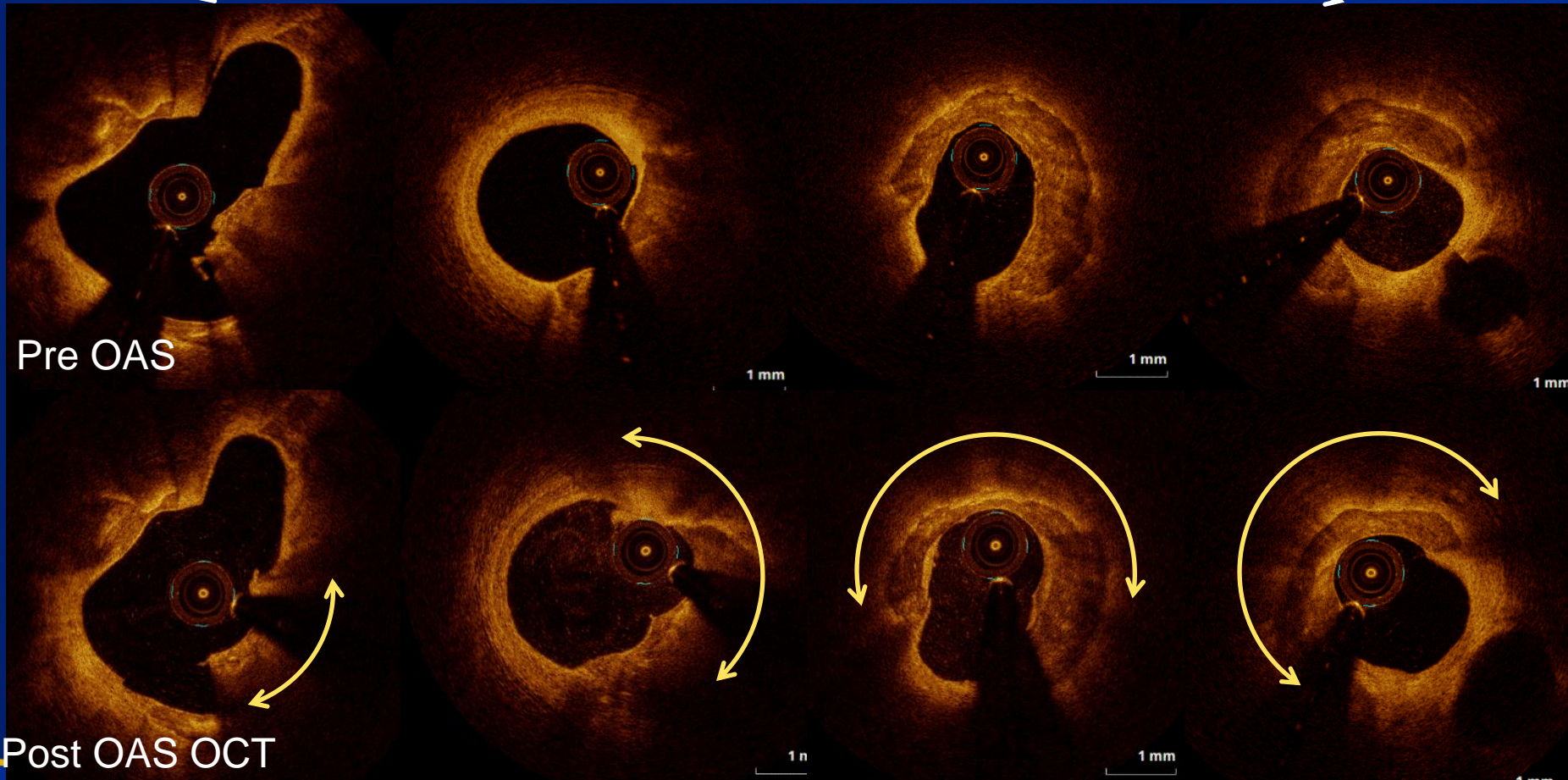
# Algorithmic Approach



# Atherectomy MOA



OAS cutting can be seen even in large lumen area or at side branch (lumen independent) at wire bias

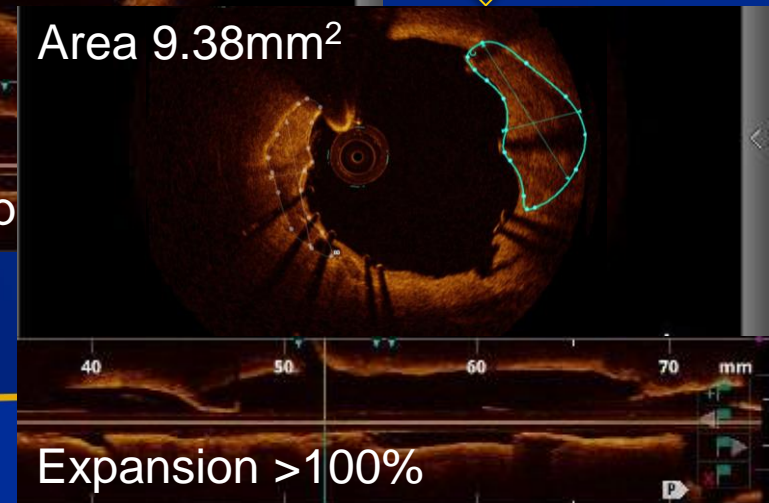
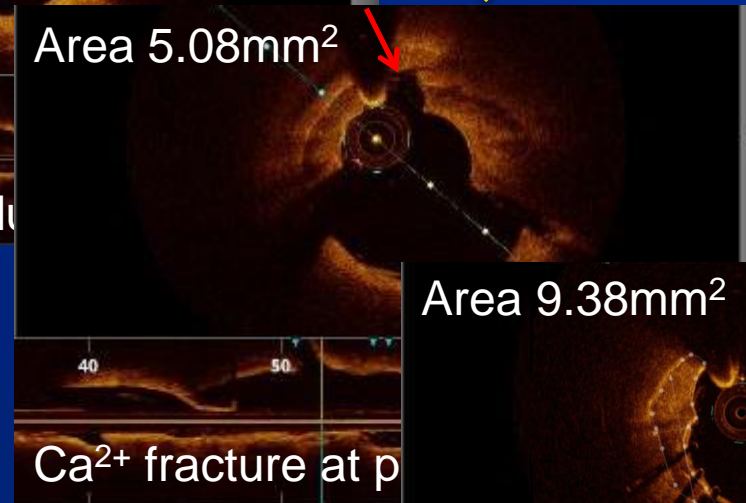
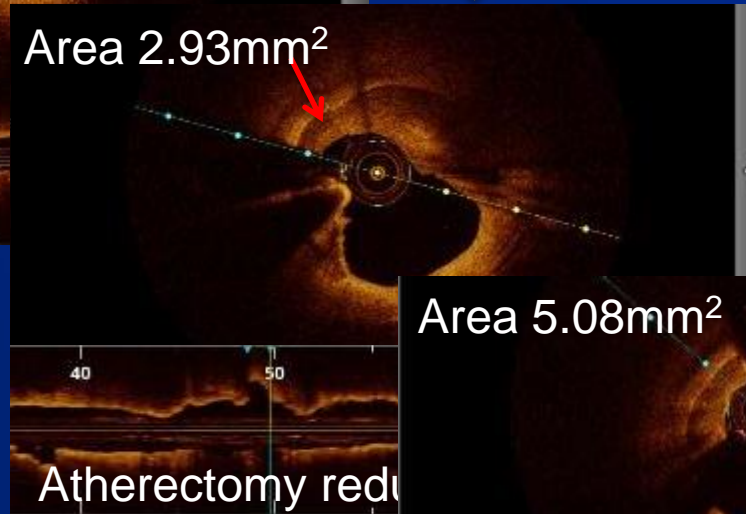
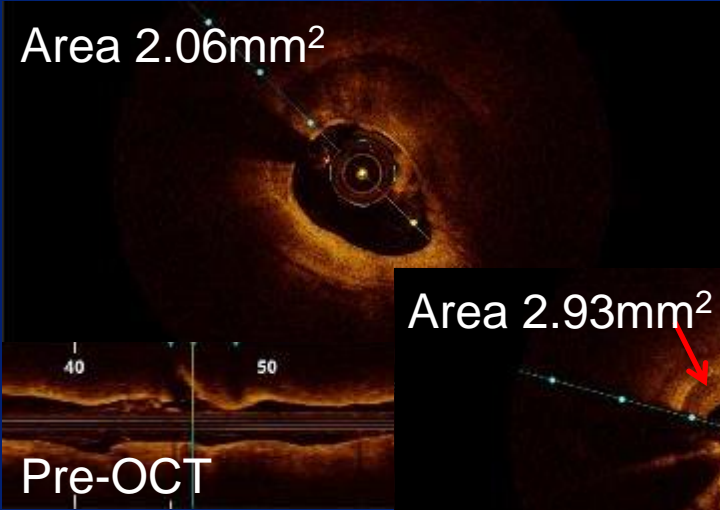


Pre OAS

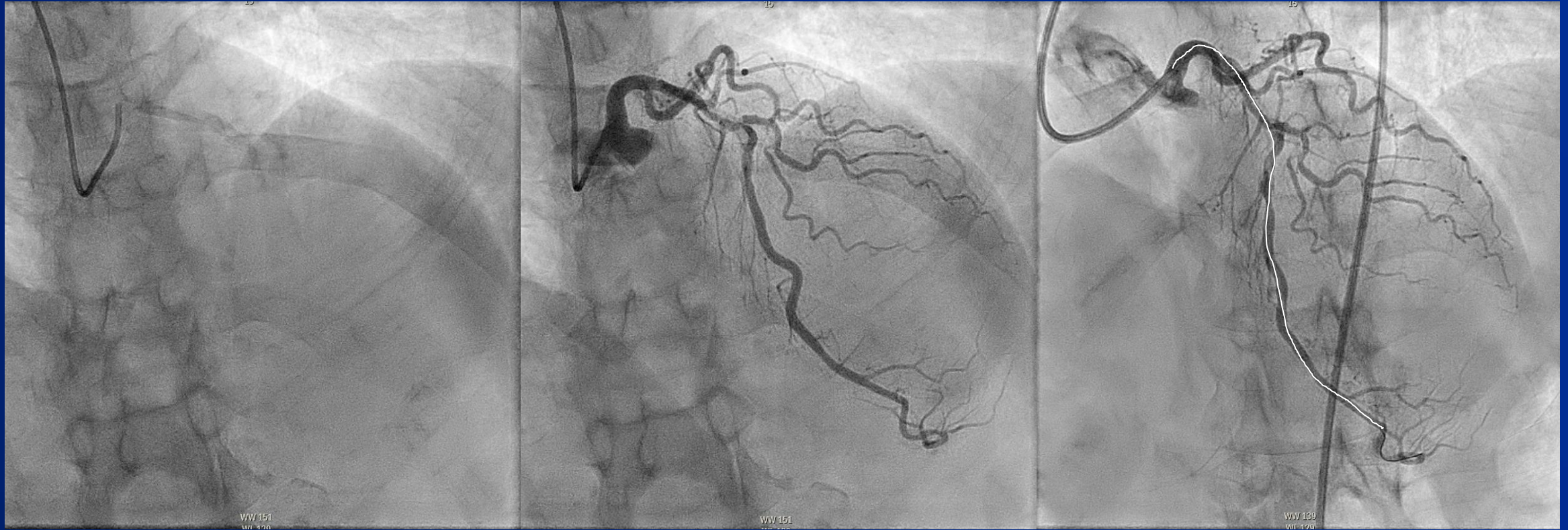
Post OAS OCT

**Favorable Wire Bias**

# Ca<sup>2+</sup>-dependent lesion Preparation

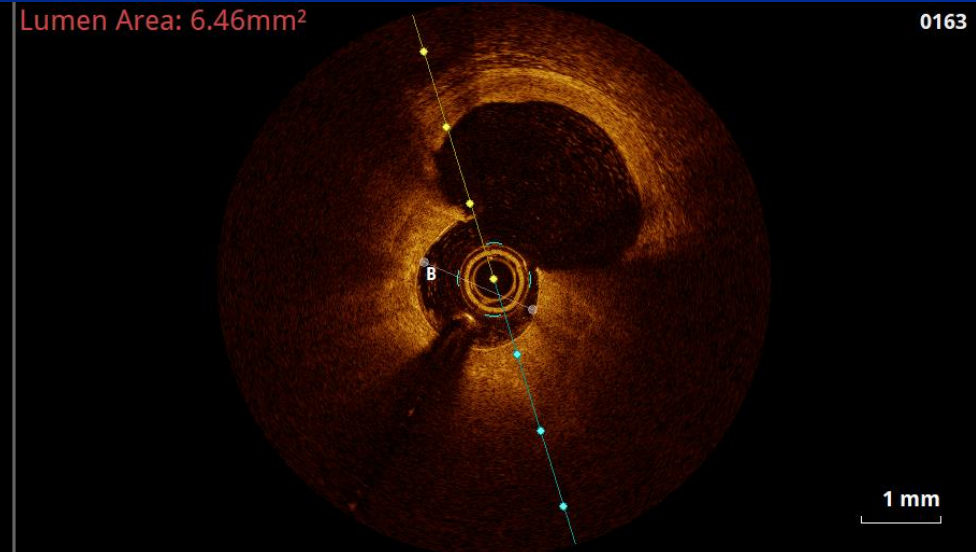
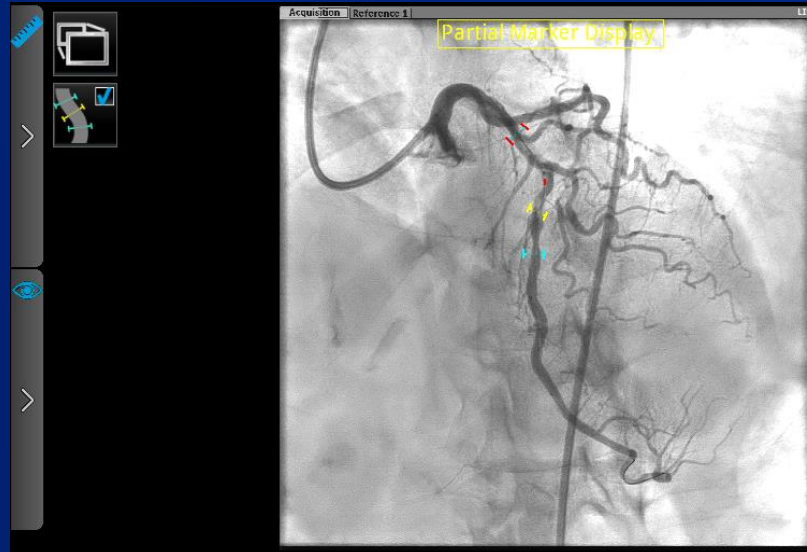


# Wire-bias dependent lesion Preparation

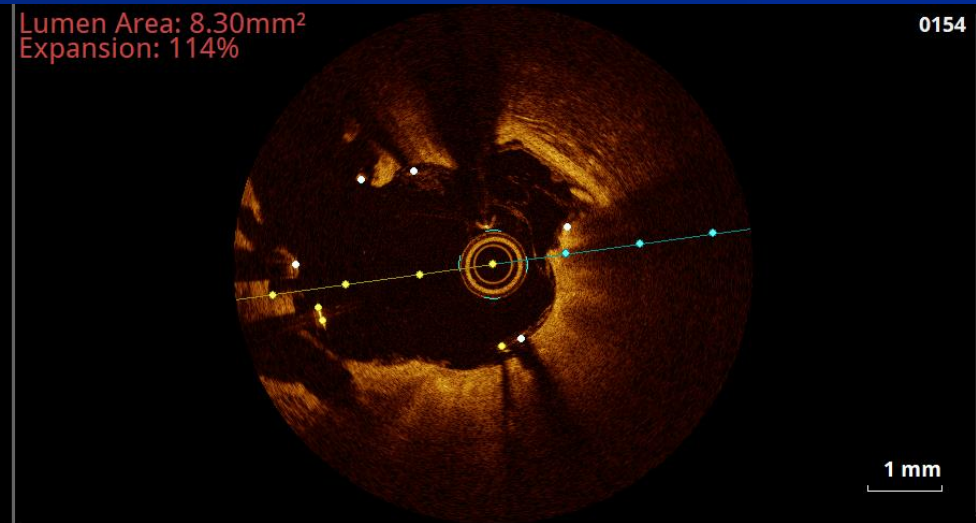
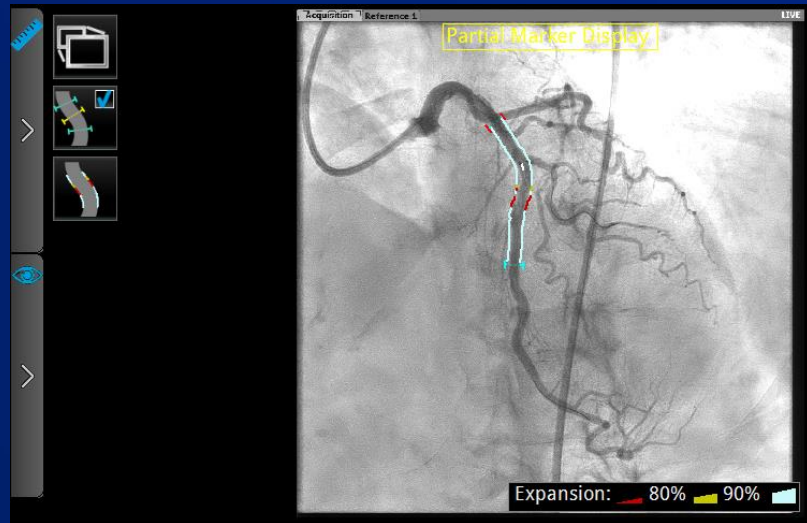


# Atherectomy – Wire Bias

Post-OAS



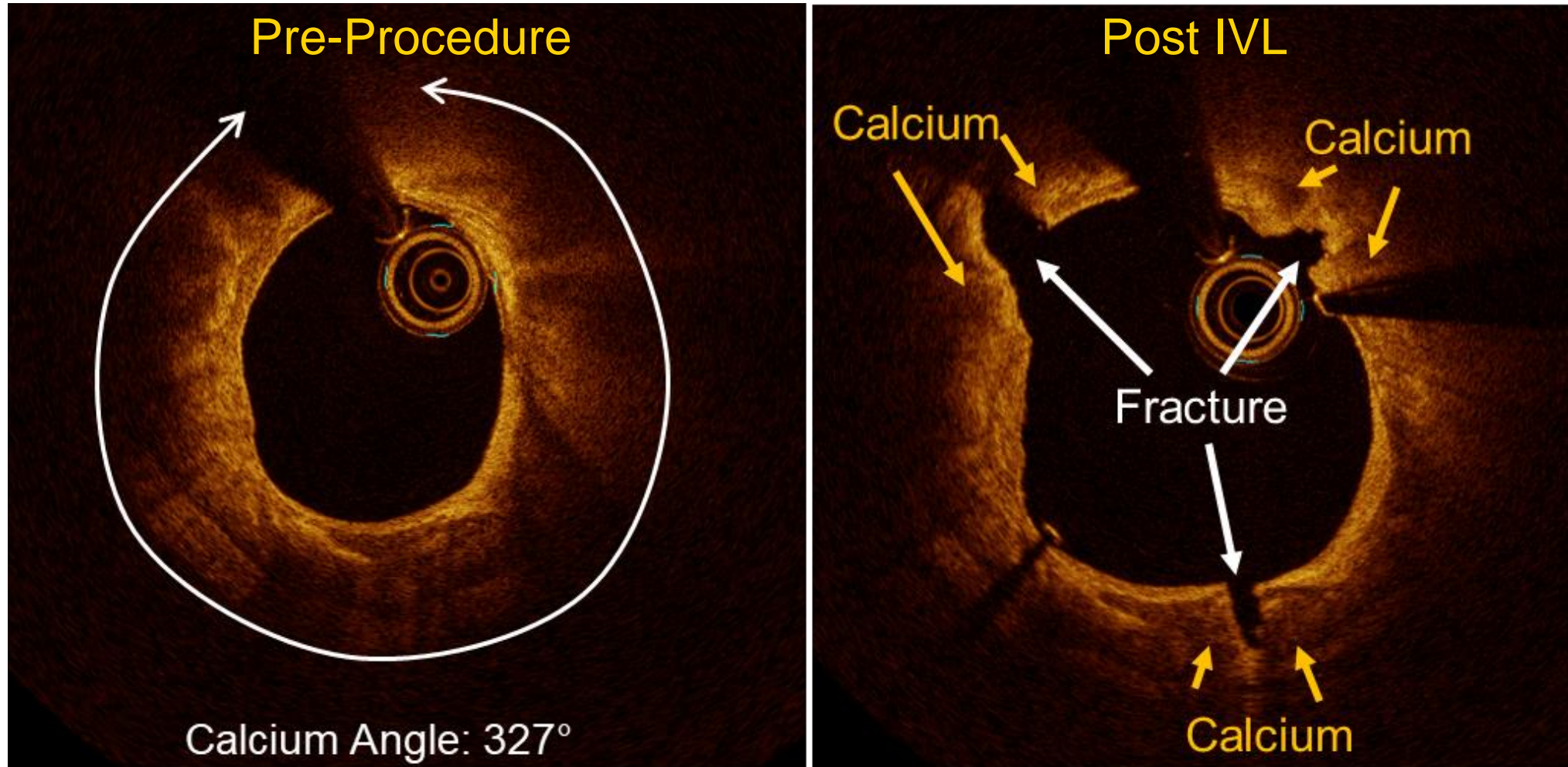
Post-DES



- In extreme angulation, atherectomy may injure the vessel wall.

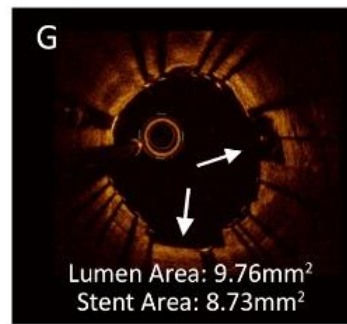
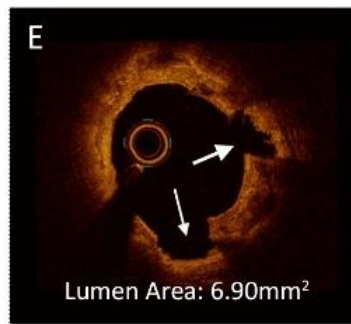
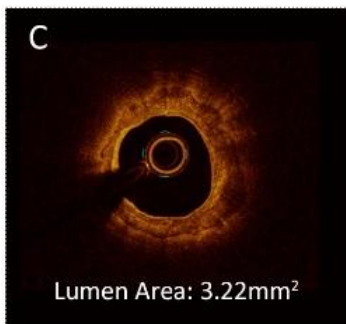
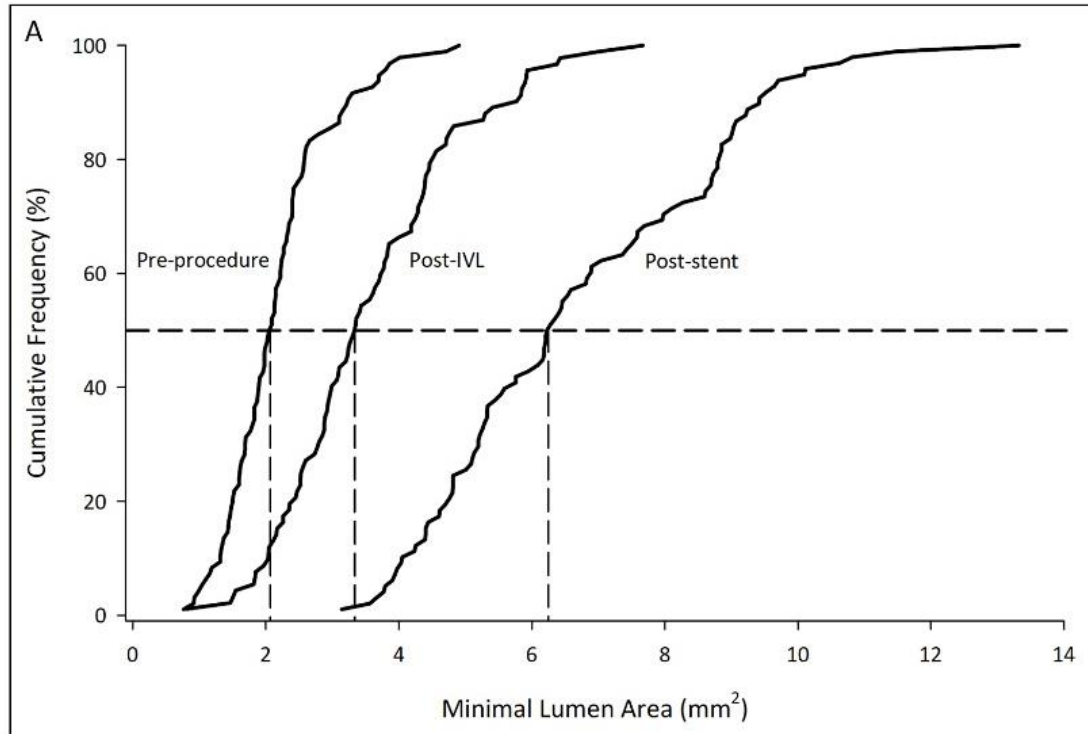
# Mechanism of Action

## Circumferential Calcium Fracture

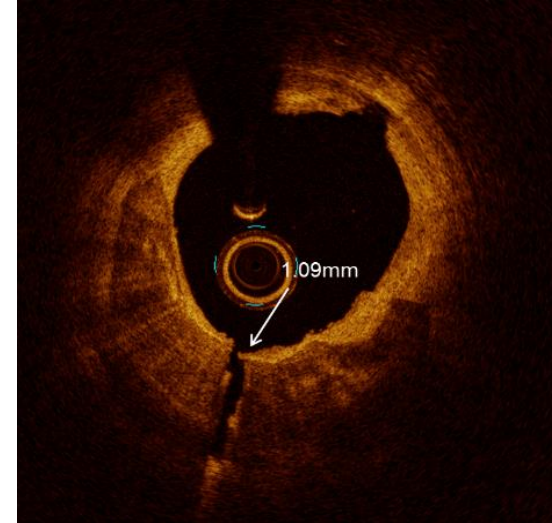


Ali and Fajadet et al. iJACC.2017;10(8):897-906.

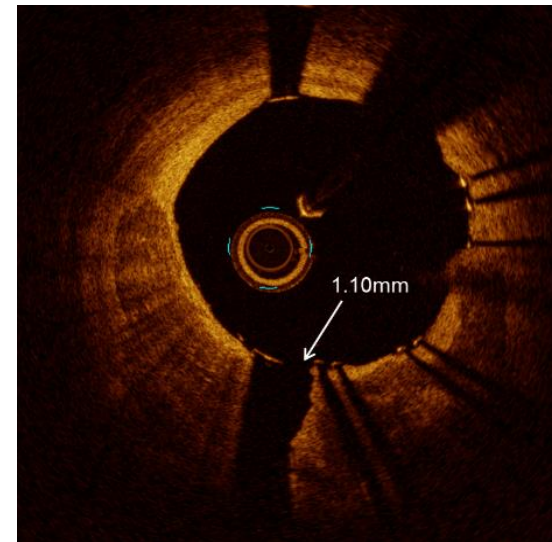
# Mechanism of Action



Post-IVL



Post-DES



Kereiakes and Ali et al. JACC Interv. 2021 28;14(12):1275-1292

# Disrupt CAD: OCT Sub-studies

## Optical Coherence Tomography Characterization of Coronary Lithoplasty for Treatment of Calcified Lesions



### First Description

Ziad A. Ali, MD, DPHIL,<sup>a,b</sup> Todd J. Brinton, MD,<sup>c</sup> Jonathan M. Hill, MD,<sup>d</sup> Akiko Maehara, MD,<sup>a,b</sup> Mitsuaki Matsumura, BS,<sup>a,b</sup> Keyvan Karimi Galougahi, MD, PhD,<sup>a</sup> Uday Illindala, MS,<sup>e</sup> Matthias Götzberg, MD, PhD,<sup>f</sup> Robert Whitbourn, MD,<sup>g</sup> Nicolas Van Mieghem, MD,<sup>h</sup> Ian T. Meredith, MBBS, PhD,<sup>i</sup> Carlo Di Mario, MD, PhD,<sup>j</sup> Jean Fajadet, MD<sup>k</sup>

**Circulation: Cardiovascular Interventions**

Volume 12, Issue 10, October 2019

<https://doi.org/10.1161/CIRCINTERVENTIONS.119.008434>

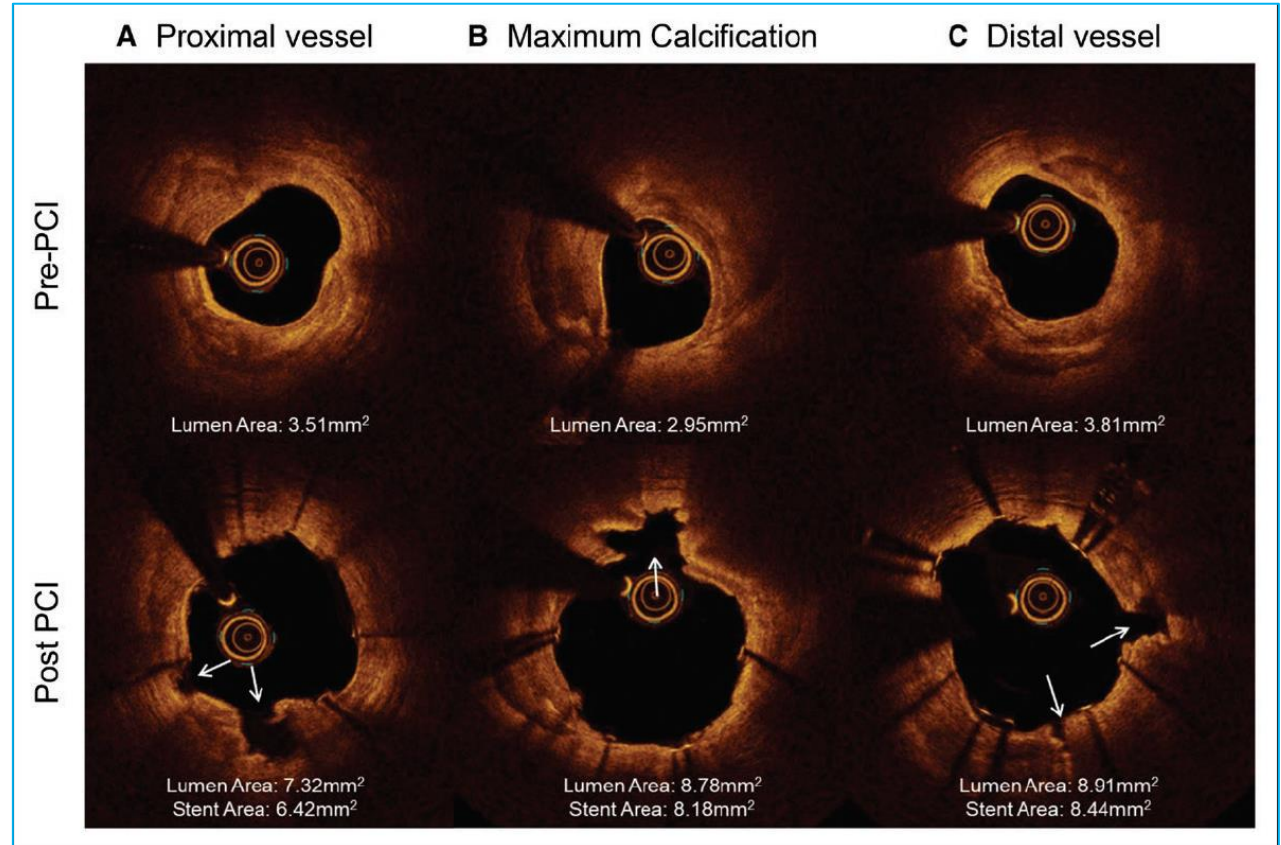


### CORONARY INTERVENTIONS

## Safety and Effectiveness of Coronary Intravascular Lithotripsy for Treatment of Severely Calcified Coronary Stenoses

### The Disrupt CAD II Study

Ziad A. Ali, MD, DPhil, Holger Nef, MD, PhD, Javier Escaned, MD, PhD, Nikos Werner, MD, PhD, Adrian P. Banning, MD, Jonathan M. Hill, MD, Bernard De Bruyne, MD, PhD, Matteo Montorfano, MD, Thierry Lefevre, MD, Gregg W. Stone, MD, Aaron Crowley, MA, Mitsuaki Matsumura, BS, Akiko Maehara, MD, Alexandra J. Lansky, MD, Jean Fajadet, MD, and Carlo Di Mario, MD, PhD

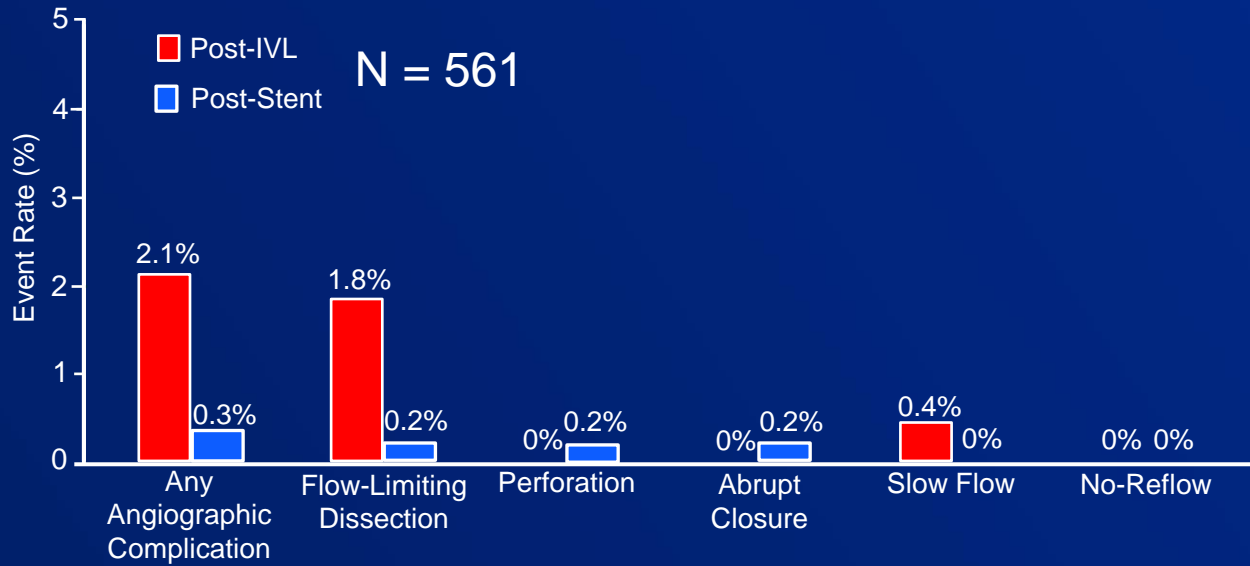


Ali et al. iJACC. 2017

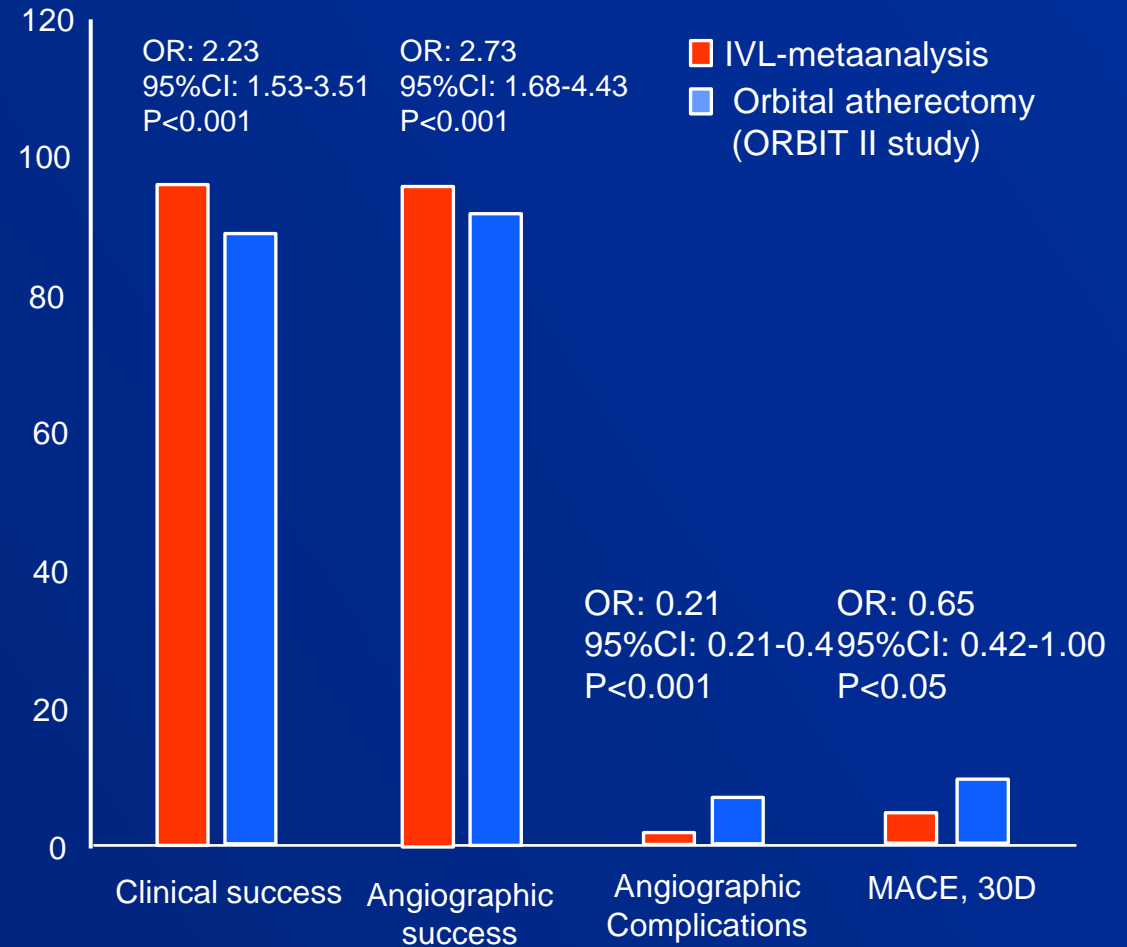
Ali et al. Circ Cardiovasc Interv. 2019

**DISRUPT CAD : OCT demonstrated multiple circumferential calcium fractures and excellent stent expansion**

# IVL Safety

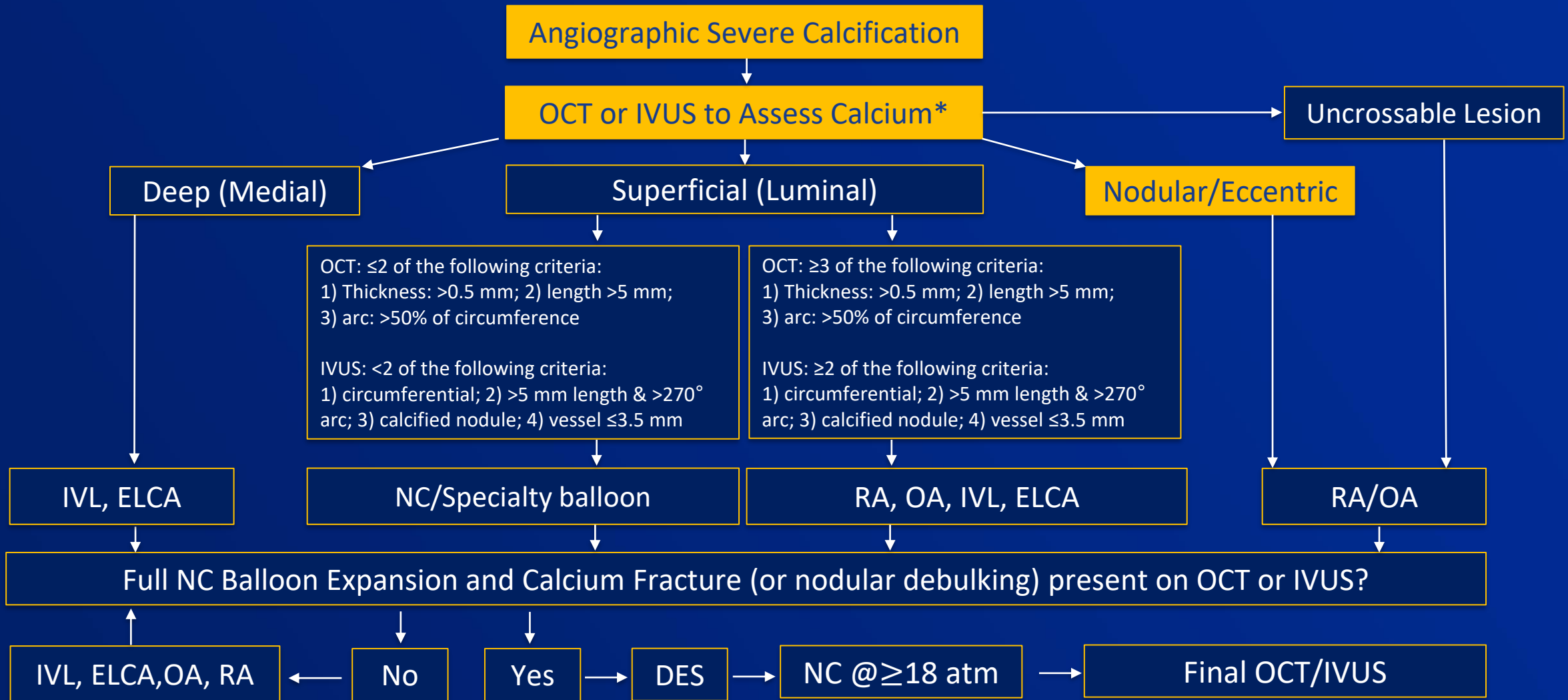


Kereiakes et al. JACC int. 2021; 14(12):1337-48



Cardiovasc Revasc Med. 2022;36:73-82

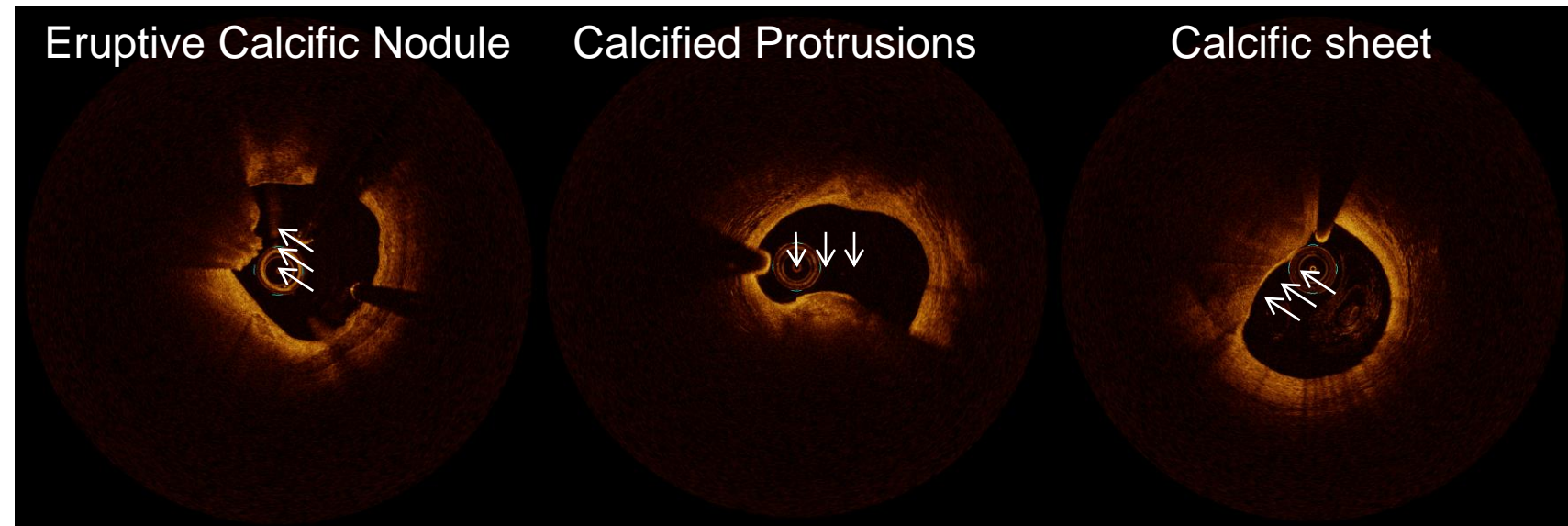
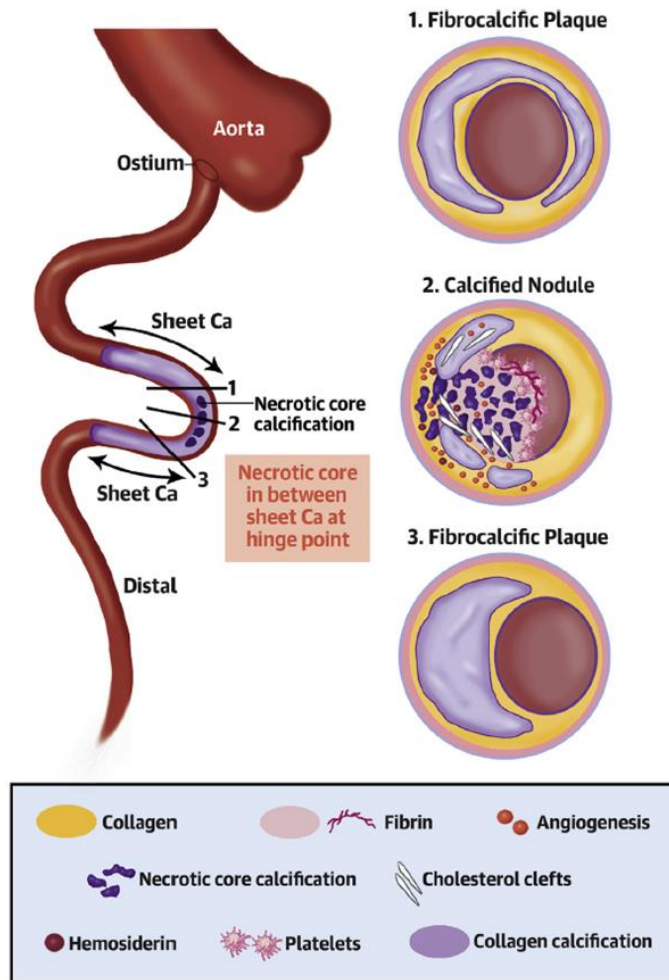
# Algorithmic Approach



# Nodular Calcium

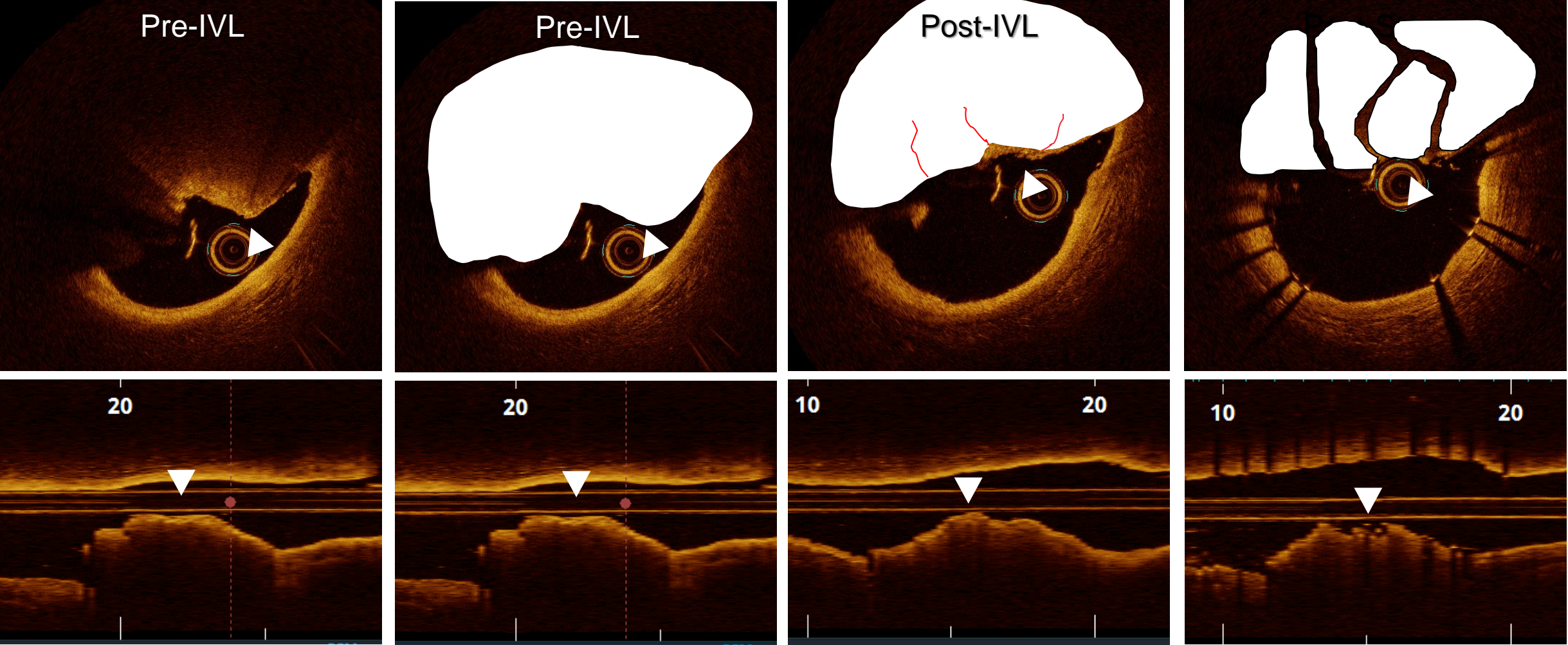
## Calcium nodule (CN)

- **Eruptive CN:** Accumulation of small calcium fragments with irregular surface and adjacent proximal or distal deep sheet calcification
- **Nodular calcification (healed calcified nodule):** Accumulation of small calcium fragments with smooth thick fibrous cap with adjacent proximal or distal deep sheet calcification



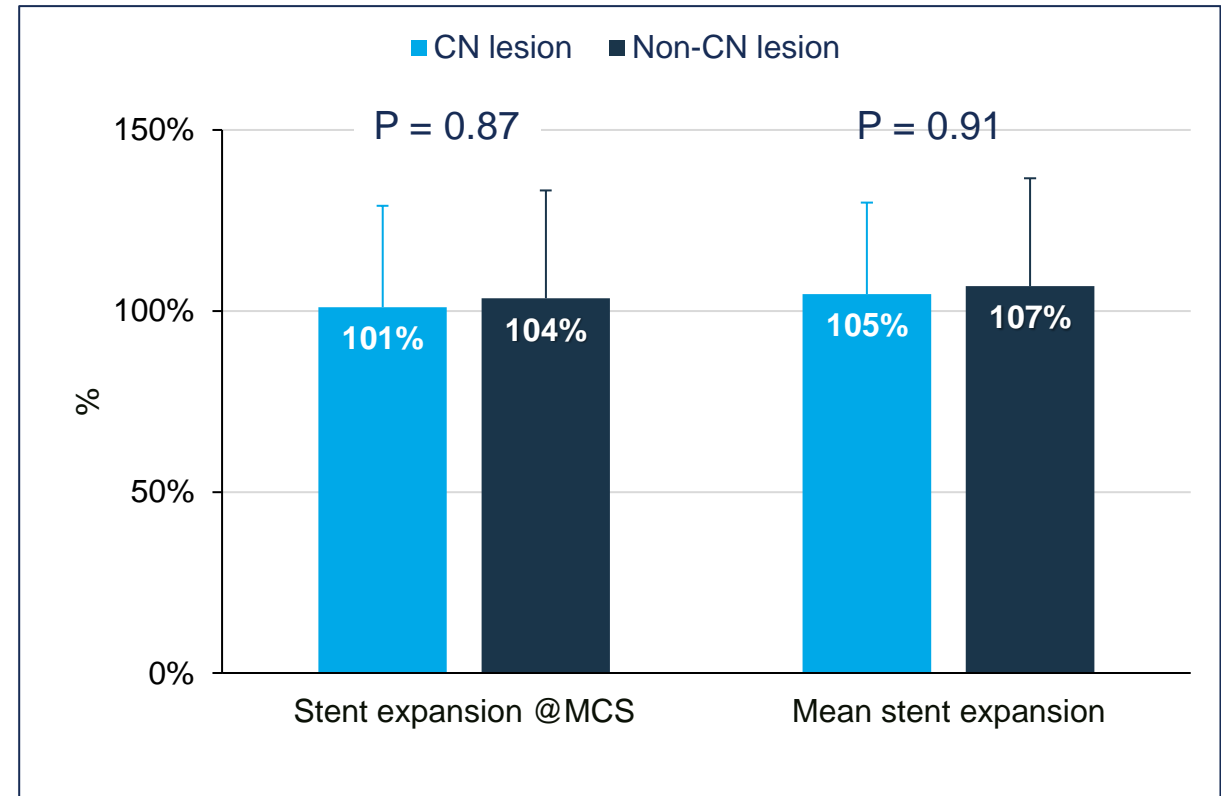
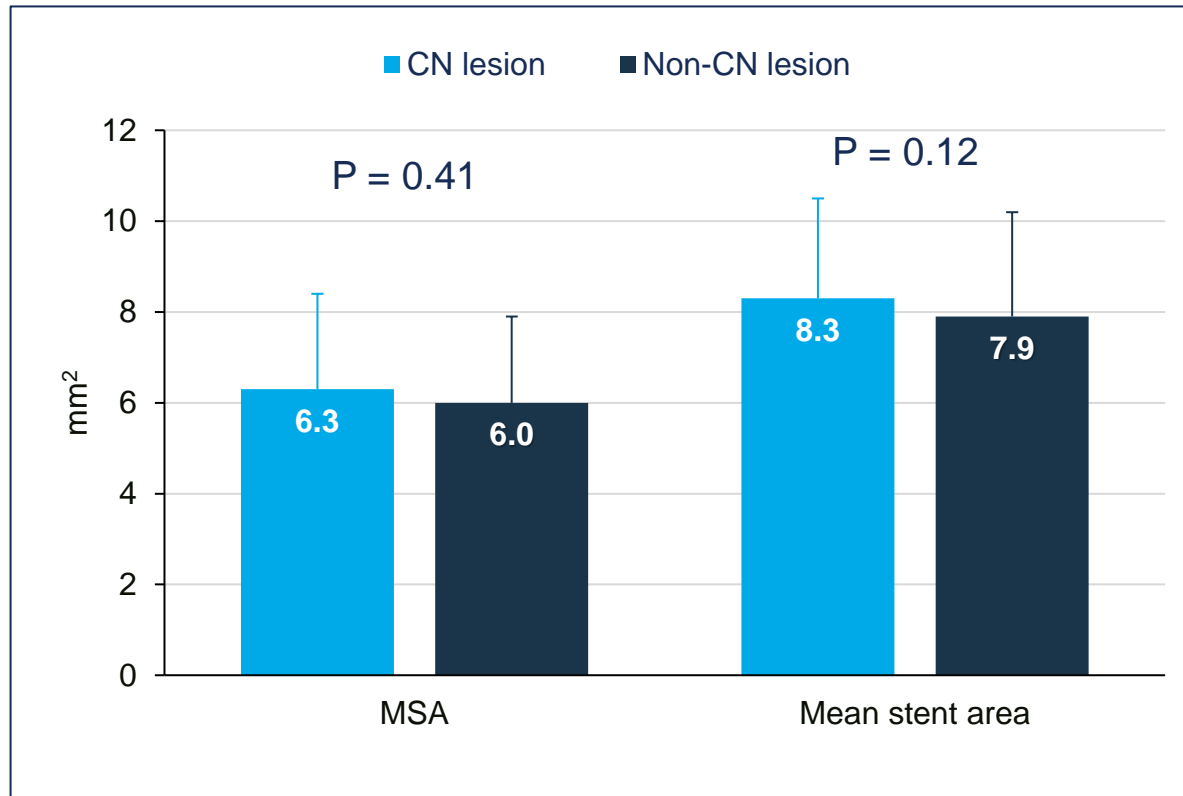
Torii, S. et al. J Am Coll Cardiol. 2021;77:1599-611. Lee, T. et al. J Am Coll Cardiol. 2017;10:883-91. Ali et al. EuroIntervention 2021;17:e105-e123.

# Nodular Calcification: IVL MOA



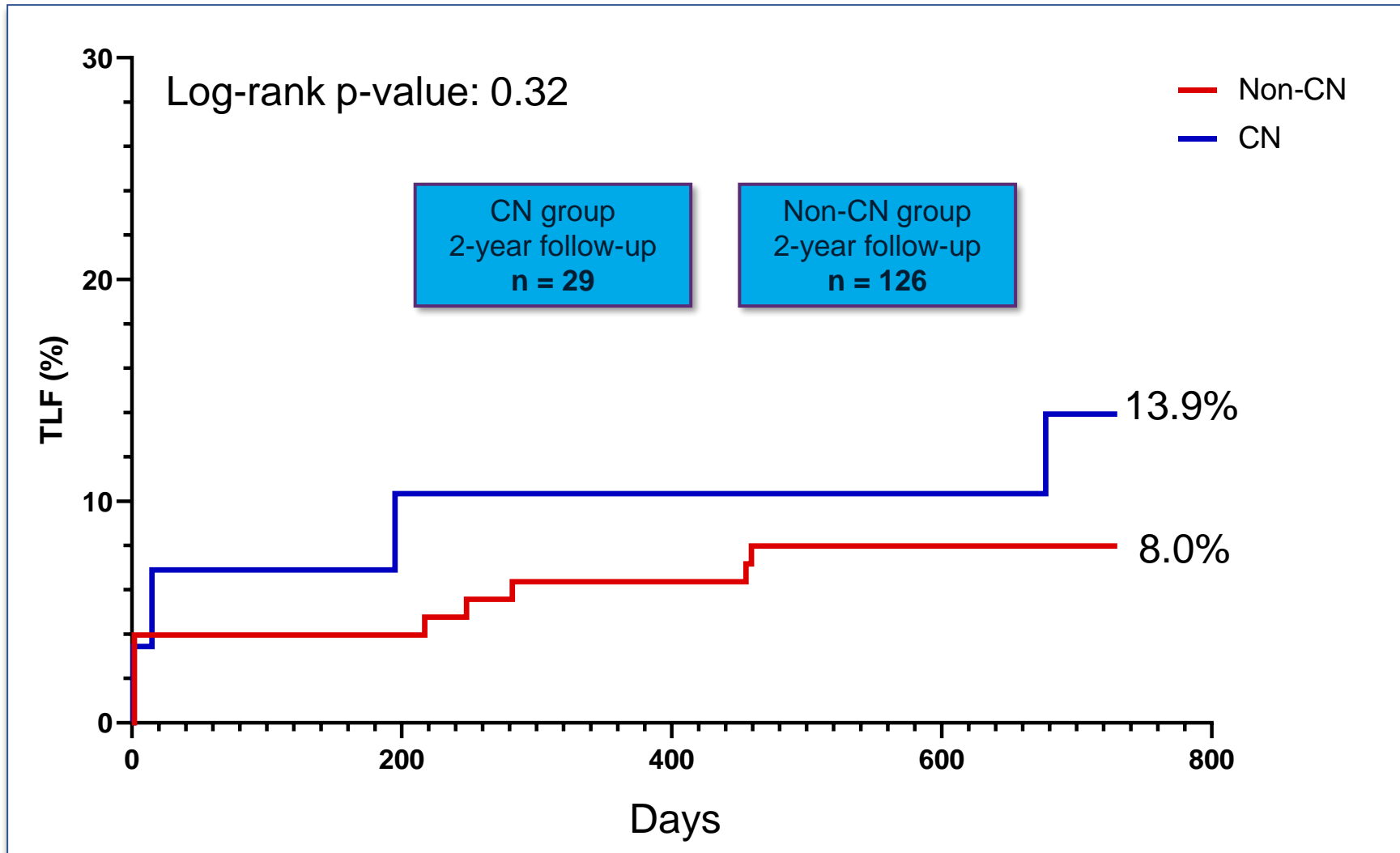
# IVL in CN Lesions

- Consistent stent expansion and MSA following IVL treatment previously demonstrated in lesions with CN
- However, the long-term clinical impact of these acute findings has not been reported

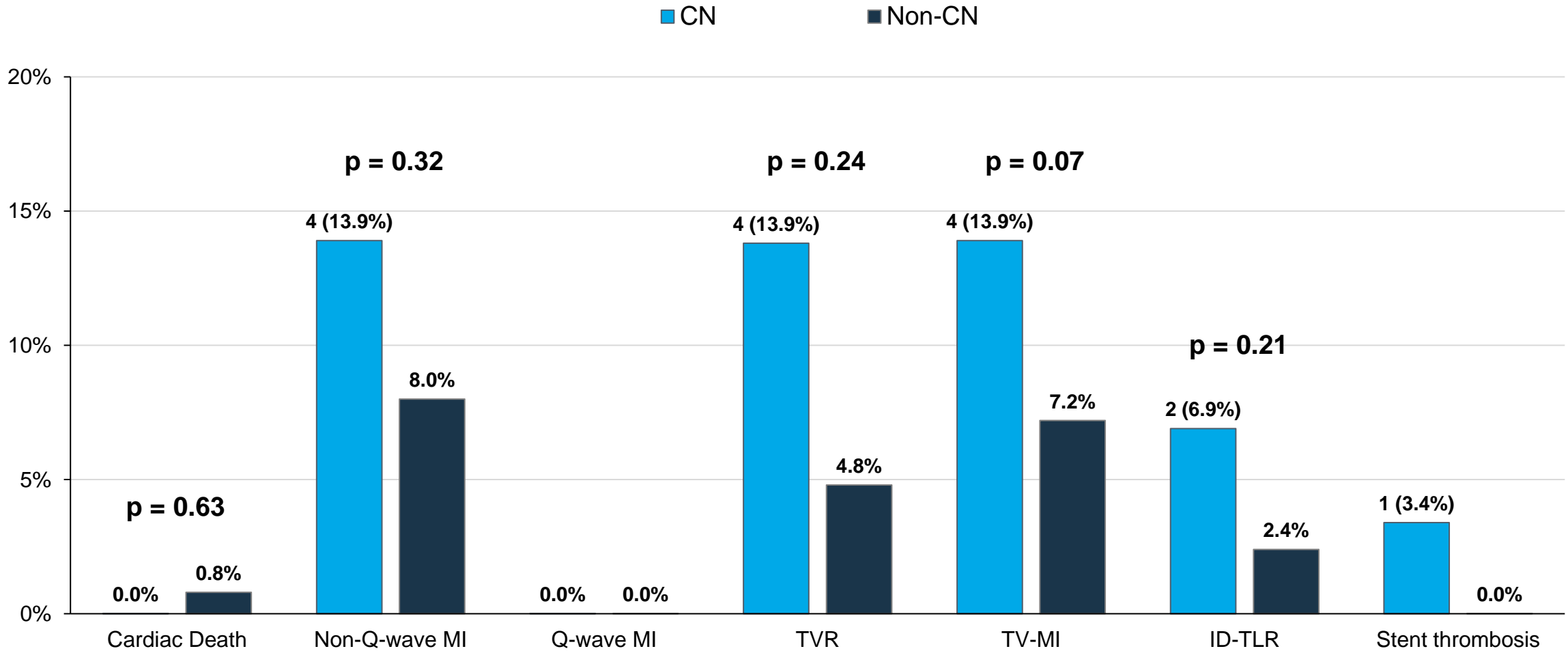


Ali Z & Shlofmitz R. (2023) *JACC Int.* In press.

# Target Lesion Failure



# 2 Year Outcomes



\*N=1 ST event at POD 22

# Conclusions

- The new algorithm;

**IVL is safe and effective across  
all calcium morphologies**

